The Eye as a Window to Systemic Health: A Survey of Retinal Imaging from Classical Techniques to Oculomics

Inamullah[a], Imran Razzak[b], Shoaib Jameel[a,*]

[a] School of Electronics & Computer Science, University of Southampton, SO17 1BJ, Southampthon, United Kingdom
[b]Mohamed bin Zayed University of Artificial Intelligence Abu Dhabi, United Arab Emirates
[*]Corresponding author: m.s.jameel@southampton.ac.uk

arXiv:2505.04006v1 [cs.CV] 6 May 2025

***Abstract*—The unique vascularized anatomy of the human eye, encased in the retina, provides an opportunity to act as a window for human health. The retinal structure assists in assessing the early detection, monitoring of disease progression and intervention for both ocular and non-ocular diseases. The advancement in imaging technology leveraging Artificial Intelligence has seized this opportunity to bridge the gap between the eye and human health. This track paves the way for unveiling systemic health insight from the ocular system and surrogating non-invasive markers for timely intervention and identification. The new frontiers of oculomics in ophthalmology cover both ocular and systemic diseases, and getting more attention to explore them. In this survey paper, we explore the evolution of retinal imaging techniques, the dire need for the integration of AI-driven analysis, and the shift of retinal imaging from classical techniques to oculomics. We also discuss some hurdles that may be faced in the progression of oculomics, highlighting the research gaps and future directions.**

***Index Terms*—Retinal Imaging, Retinal Vasculature, Oculomics, Systemic Diseases, Artificial Intelligence, Deep Learning, Retinal Biomarkers, Phenotypes, Genotypes**

I. Introduction

The retina, the crucial light-sensitive tissue at the back of the eye, is a treasure trove of insights for ophthalmologists, clinicians, and technicians. It plays a pivotal role in the early prediction and intervention of both ocular and non-ocular disorders. Retinal imaging (RI), a key interpretation, encompasses a variety of techniques designed to visualise and analyse the retina [1]. Fundus photography (FP) captures detailed, subtle changes in the ocular system, while optical coherence tomography (OCT) provides a cross-sectional view, and OCT angiography (OCTA) visualizes blood flow. These modalities, serving as vital diagnostic tools, enable healthcare professionals to examine the intricate structure of the retina, including the macula, optic disc, and retinal vasculature. This non-invasive assessment allows for the early detection and monitoring of ocular diseases like diabetic retinopathy (DR), glaucoma (GL), macular degeneration (MD), and other related diseases that can lead to significant vision impairments if left unattended [2].

Beyond ocular health, RI also provides insight into detecting systemic diseases. The retina's unique accessibility and the visibility of its microvasculature make it a valuable indicator of overall health. For example, changes observed in the blood vessels and layers of the retina can trigger cardiovascular (CV) and cerebrovascular diseases. That is why the eye serves as a window of overall health in the association of ocular and systemic health. High-resolution imaging can further reveal fine-grained features and act as a facilitator for timely intervention and personalised care. This contributes to improved patient outcomes and a better understanding of the interrelation between bodily systems [3], [4].

Oculomics studies ocular biomarkers, using advanced imaging technologies to probe the eye in relation to other organ systems through shared physiological functions, embryological origins, and anatomical structures. It aims to establish correlations between these markers and systemic diseases. Growing evidence indicates that oculomics is significant in identifying clinical manifestations in ocular markers, such as retinal vessel patterns and neural layer thickness, which can reveal the presence of systemic diseases such as diabetes, CV diseases (CVDs), neurological issues, and stress-related disorders. This field is driven by three significant advances, including the widespread availability of high-resolution ophthalmic imaging, the emergence of big data, and the development of automated artificial intelligence (AI) software. Together, it has the potential to revolutionise disease management by providing a comprehensive and accessible approach to monitoring and maintaining human health [5], [6].

AI is at its peak in the era of big data and parallel processing. The AI model is based on recorded data, and disciplines with data can easily participate in it. In the current epoch, it is hard to conclude that there may be fields in academia and industry that can thrive without data. Therefore, no discipline will be empty-handed when discussing data. AI models are now prevalent and deployed in every aspect of life [7]. Both intrinsic and extrinsic deployments have positively impacted our society, especially in socioeconomic and socio-health aspects. Renowned computer scientist Dr. Knuth revealed that biology has at least 500 years of exciting problems to explore [8]. This perspective encourages the computing and biomedical research communities to address challenges in life science collaboratively.

AI is transforming RI and ocular studies by automating and enhancing the analysis of complex visual data. AI algorithms, especially deep learning (DL), excel in identifying subtle patterns and abnormalities within retinal images that human observers might overlook. This automation significantly speeds up the screening process for ocular and non-ocular diseases,

allowing for earlier detection and intervention. In addition, AI can enable the development of predictive models by evaluating the vast data set, encompassing the assessment of the individual patient's risk factors and anticipating disease progression, paving the way for personalised medicine in ophthalmology [9]–[11].

Eye diagnostic research is shifting from its classical origin to the current AI software tools. Now, it's beyond the classical methods, such as preprocessing, model training, and limited clinically relevant output. These limited circumstances hinder the quantification of retinal structures at the minute and micro levels to address the objective measurements, which are crucial for the efficacy of effective treatments and the monitoring of disease progression in the growing field of oculomics. Likewise, for meaningful research, high-quality and large health datasets comprising rich annotated data are crucial, which advances the role of statistical, computational, and AI-driven techniques [12], [13]. Furthermore, this framework can be further nourished by integrating retinal imaging with clinical information, namely electronic health records (EHRS) and genetic data, including diverse demographic and ethnic data. However, translating this vision into practice remains a considerable challenge. Existing datasets often lack the necessary integration across epidemiological, clinical, and imaging domains, limiting the development of a unified infrastructure supporting oculomics research and clinical application [4], [14], [15].

Despite the increasing availability of large-scale datasets, significant limitations impede their practical use in oculomics. Even though there are several Retinal imaging repositories, including those of Moorfields Eye Hospital [16], UK Biobank [17], and the 10k Cohort [18], access to these resources is often restricted to trusted research environments due to anonymisation protocols. Moreover, much of the publicly available data lacks critical demographic and ethnic metadata, with estimates suggesting that approximately 74% of these datasets do not include such information. As a result, even healthcare providers with extensive retinal image collections, ranging from ten thousand to ten million scans, face challenges in generating truly representative [19], integrative datasets.

More broadly, a substantial gap exists in integrating retinal imaging data with molecular, clinical, and diverse datasets. Such integration is crucial for capturing the multi-dimensional nature of complex diseases [20]. However, epidemiological models, such as cohort, longitudinal and population-based studies, have successfully mapped disease trajectories in other domains [21]; their application to oculomics remains onerous [4]. The combined burden of global communicable and non-communicable diseases has further highlighted the need for such inclusive, multi-modal datasets that account for diversity across ethnicity, age, and geography [22].

These shortcomings highlight the urgent need for a next-generation framework to unify fragmented data sources and enable deeper clinical insights. This includes robust epidemiological frameworks, large-scale imaging biobanks, and AI-enabled platforms harmonising disparate data types. Unified and multidimensional data frameworks—incorporating molecular signatures, imaging biomarkers, and longitudinal clinical profiles—hold the potential to provide a more holistic understanding of disease onset and progression. These frameworks, already successful in fields like oncology and cardiology [23], are both timely and necessary for their adoption in oculomics [5].

As a result of these converging needs and opportunities, oculomics has emerged as a leading frontier in multimodal healthcare research, with biomarkers to infer both ocular and systemic health [24]. The retina is uniquely positioned for this purpose due to its rich vascular and neural architecture, which reflects broader physiological states throughout the body. As a transparent and non-invasive window into the vascular and neurobiological environment, RI allows early detection of systemic conditions. This makes the retina an ideal candidate for multimodal investigation in both research and clinical settings [25].

Recent developments in automated image analysis tools have further enhanced retinal imaging capabilities. The AutoMorph software developed by Zhou et al. [1] enables a precise, large-scale extraction of morphological features from the retinal vasculature in a fully automated pipeline. This advancement significantly supports high-throughput oculomics research by offering standardised and scalable morphological analysis of retinal structures.

In recent years, oculomics has emerged as a highly interdisciplinary domain, yet there remains a lack of cohesive literature synthesising its technological, clinical, and methodological advancements. Most existing reviews focus either on specific imaging techniques or isolated systemic diseases, without bridging the broader implications of AI-powered retinal analysis for integrated healthcare [6], [26]–[29]. Given the rapid development of retinal image processing tools, dataset accessibility, and AI-driven diagnostic models, a comprehensive review is now both necessary and timely. This survey aims to fill that gap by contextualising classical foundations, highlighting cutting-edge innovations like AutoMorph, and proposing a unified framework for future research. This survey paper presents a structured synthesis of advancements in retinal imaging, AI integration, and multi-modal health data. It highlights key breakthroughs, identifies current gaps in clinical translation, and offers a roadmap for future interdisciplinary collaborations in oculomics. Through this, we aim to support the development of robust, explainable, and scalable tools capable of revolutionising healthcare delivery across disciplines.

II. Ocular Anatomy and Physiology & Historical Perspective on Eye Disease Research

A. Ocular Anatomy and Physiology

The field of ophthalmology has undergone significant evolution, marking a remarkable advancement in understanding, diagnosing, and treating eye diseases over the centuries. This evolution is driven by the imperative to comprehend a variety of ocular conditions arising from the diverse cellular, tissue, and neural components present within the eye. Each of these components is intricately linked to specific diseases, highlighting the necessity of studying the eye's anatomy for improved

diagnostic and early intervention strategies. Among these anatomical structures, externally visible components such as the cornea, iris, and pupil are essential for regulating light entry. In contrast, internal structures, namely the lens, retina, and optic nerve, play critical roles in visual processing and are central to clinical imaging and disease detection.

The visible components of the human eye include the cornea, iris, and pupil portrayed in Figure 1. The cornea, a transparent, curved structure, serves as the outermost layer of the eye, while the iris, the colored part of the eye, may manifest in various hues such as blue, green, or brown. Central to these features is the pupil, which appears black. Through fundoscopy, retinal images reveal deeper anatomical structures, as shown in Figure 2 (b). The cornea functions predominantly as a refractive lens, contributing approximately three-fourths of the eye's focusing power, with the remaining one-fourth attributed to the actual lens. Light passes through the pupil and the lens before reaching the retina, traversing the vitreous humour, a gel-like substance that maintains ocular shape, supports the retina, and facilitates proper optical functioning.

The retina, situated at the posterior aspect of the eye, is a critical structure sensitive to light. Cross-sectional analysis of the retina uncovers six distinct classes of neurons (Figure 2 (b)): cones, rods, amacrine cells, horizontal cells, bipolar cells, and ganglion cells. Each neuron type performs specific functions, yet collectively contributes to the overall process of vision. The retina is further encased by the choroid, illustrated in Figure 2 (a), with the optic nerve transmitting visual information to the brain's visual cortex, culminating in the perception of sight. Notably, the macula functions as the eye's focal point, wherein central vision is processed [30], [31].

Although the retina is often described as opaque, it is dependent on the support of the retinal pigment epithelium, choroid, and sclera. The choroid and retinal vasculature supply approximately 65% and 35% of the blood flow to the retina, respectively. A plethora of significant diseases can manifest within the retina, with origins either localised to the eye or connected to systemic conditions. As disorders affecting any of these anatomical components can lead to substantial visual impairment, a profound understanding of ocular anatomy and physiology is essential for effective diagnosis and treatment [32]. This section discusses several diseases, with additional conditions to be explored in forthcoming sections, addressing various aspects pertinent to ocular health.

B. Historical Perspective of Eye Diseases Research: From Ancient Techniques to Modern AI-Driven Oculomics

The study of the eye and associated diseases dates back to ancient civilisations, where early contributions focused on anatomy, diseases, and basic treatments. Over the centuries, the field of ophthalmology has evolved significantly, driven by the pressing need to understand, diagnose, and treat eye diseases. Today, AI integration has revolutionised the field, enabling unprecedented advances in diagnostics, treatment, and research. This section traces the historical journey of eye disease research, from ancient techniques to the era of classical AI and modern deep learning, culminating in the emerging field of oculomics.

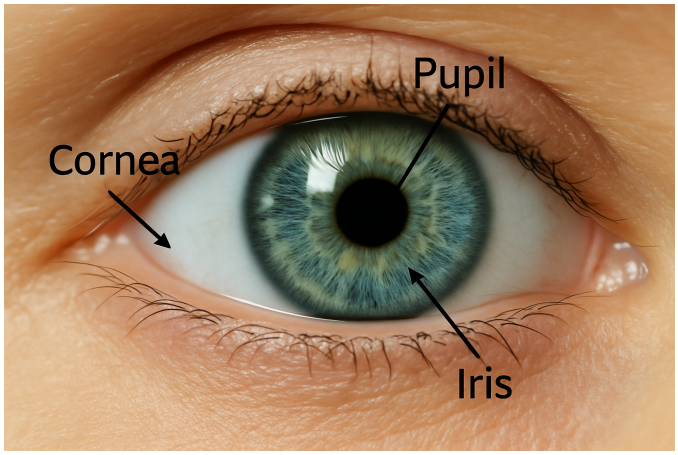

Fig. 1. External anatomy of the human eye, showing the cornea, iris, and pupil. These structures regulate how light enters the eye and initiate the visual processing pathway

*1) **Pioneer Surgical and observational Techniques**:* The study of the eye dates to ancient civilisations, where early contributions focused on ocular anatomy, diseases, and basic treatments. Cataracts were among the first documented eye diseases, dating back to around 600 BCE. The Sushruta Samhita, an ancient Indian medical text, described a surgical technique called "couching", where the opaque lens was inserted into the vitreous humour to restore some vision [33]. However, insertion often led to complications, for instance infection and blindness, underscoring the limitations of early surgical techniques. Greek scholars Hippocrates (460–375 BCE) and Galen (129–216 CE) founded anatomical descriptions of the choroid, lens, and optic nerve. Their work provided the foundation for understanding ocular anatomy, but their reliance on animal dissection led to inaccuracies [34]. Islamic scholars like Al-Zahrawi and Ibn al-Haytham improved surgical tools and advanced optical studies, connecting anatomy with light refraction. Ibn al-Haytham's Book of Optics emphasised the principles of vision and optics, enabling a framework for understanding refractive errors [35].

*2) **Early Breakthrough in the optical imaging**:* The development of the ophthalmoscope by Hermann von Helmholtz in 1851 was a transformative milestone. This device enabled clinicians to visualise the retina and optic nerve directly, facilitating diagnosing of conditions such as retinal detachment and optic neuritis [36]. However, the initial iterations of the ophthalmoscope required considerable skill for effective use, limiting its broader adoption in clinical practice. The early twentieth century saw significant progress in tackling prevalent eye diseases such as trachoma and cataracts. Trachoma, a bacterial infection caused by Chlamydia trachomatis, was a leading cause of blindness in low-income regions. Public health campaigns focusing on hygiene, antibiotic use, and surgical interventions significantly reduced its prevalence. However, these efforts were limited to localised outbreaks and lacked global coordination [37].

*3) **Technological and optical imaging advancement during the Mid-20th Century**:* The invention of fundus photography in the 1920s enabled static documentation of the retina,

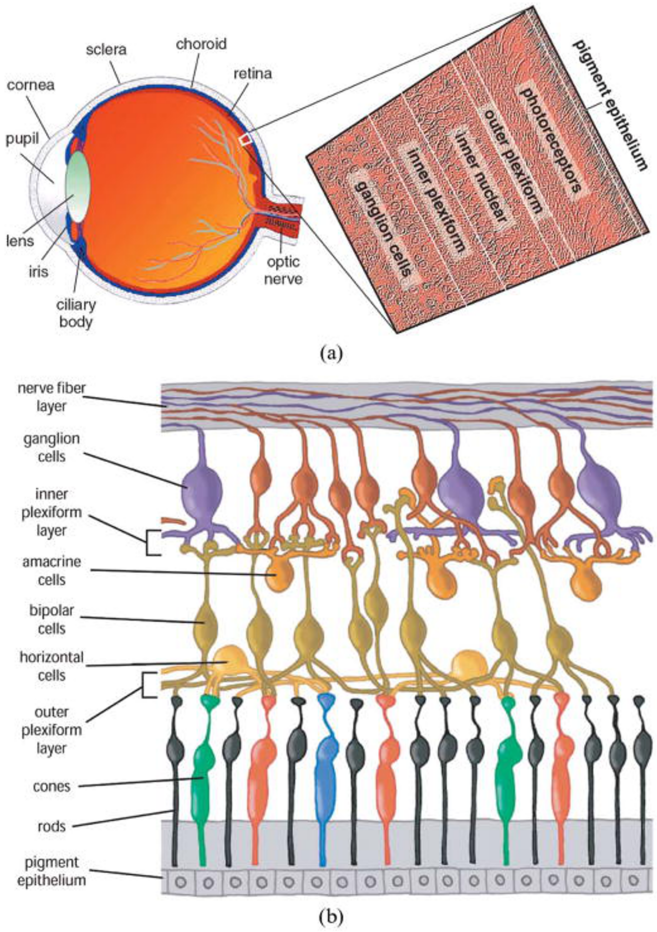

Fig. 2. Detailed cross-sectional illustration of the human retina and associated neuronal layers. Image reproduced from [32]

providing a foundation for modern retinal disease research. While this innovation allowed for detailed visualisation, early cameras suffered from low resolution and were not widely accessible. Cataract extraction methods improved with the introduction of intracapsular cataract extraction. However, the lack of intraocular lenses meant that visual outcomes were suboptimal, requiring patients to use thick corrective lenses post-surgery.

The mid-20th century saw rapid advancements in imaging and treatment technologies. In the 1960s, fluorescein angiography allowed for dynamic retinal and choroidal vasculature imaging. It became a critical tool for diagnosing retinal vein occlusion and diabetic macular edema (ME). However, the invasive nature of dye injection posed risks to patients with allergies or comorbidities [38]. Laser treatments became the standard for managing proliferative DR (PDR) and retinal detachment. While effective, these treatments were limited to advanced stages of the disease and could not prevent disease onset. Tonometry was standardised as a reliable method for measuring intraocular pressure, enabling earlier detection of glaucoma. However, tonometry alone could not detect optic nerve damage, highlighting the need for complementary diagnostic tools [39], [40].

*4) **The Emergence of Digital Era and AI in Ophthalmology**:* The digital era introduced technologies that significantly enhanced the precision and accessibility of ophthalmic diagnostics. Optical coherence tomography (OCT), invented in 1991, provided cross-sectional imaging of retinal layers with micrometre resolution . This technology revolutionized the management of MD , DR , and GL, but early devices were expensive and required significant expertise [41]. Early computational models automated tasks like vessel segmentation and lesion detection. While these methods were groundbreaking, they were limited by small datasets and reliance on handcrafted features. Digital FP enabled large-scale DR screening programs. These initiatives demonstrated the feasibility of integrating technology into public health but faced challenges in reaching rural and underserved populations [11], [32]. The integration of AI into eye disease research began with classical machine learning (ML) algorithms, which laid the foundation for automated analysis of retinal images and clinical data. Early ML models, such as Support Vector Machines (SVM), Random Forests (RF), and k-Nearest Neighbours (k-NN), were used for tasks like lesion detection, disease classification, and retinal vessel segmentation. These models relied on handcrafted features extracted from FP and OCT images, which limited their generalizability and scalability [42]–[45] For example, SVMs were employed to classify DR stages based on features, namely microaneurysms (MAs), hemorrhages(HMs), and exudates(EXs). However, these models struggled with the variability in image quality and the complexity of retinal structures. Despite these limitations, classical ML algorithms demonstrated the potential of AI in automating ophthalmic diagnostics and reducing the burden on clinicians.

*5) **Early Deep learning models in Eyes research**:* The advent of deep learning, particularly Convolutional Neural Networks (CNNs), marked a paradigm shift in the analysis of ophthalmic imaging. Unlike classical ML, CNNs automatically learn hierarchical features from raw images, eliminating the need for manual feature engineering. This capability made CNNs highly effective for tasks like DR detection, glaucoma diagnosis, and age-related macular degeneration (AMD) classification. One of the earliest breakthroughs in deep learning for ophthalmology was the development of algorithms for the screening of DR using fundus images. Studies demonstrated that CNNs could achieve a good diagnostic accuracy comparable to that of human experts [46], [47]. For example, the InceptionV3 and ResNet architectures were widely adopted for DR classification, achieving high sensitivity and specificity in detecting early-stage disease. Similarly, CNNs were applied to OCT images for the automated detection of retinal pathologies such as ME, choroidal neovascularization, and retinal detachment. These models improved diagnostic accuracy and reduced the time required for image analysis, enabling faster decision-making in clinical settings.

*6) **The Rise of pre-trained AI Models and Multimodal Data Integration** :* CNNs revolutionized ophthalmic imaging, but their limitations in capturing long-range dependencies and spatial relationships led to the development of Vision Transformers(ViTs) [48]. Inspired by the success of transformers in natural language processing, ViTs introduced self-attention

mechanisms to image analysis, enabling better modelling of global context and spatial relationships within medical and optical imaging. ViTs have been applied to tasks like DR grading, AMD classification, and retinal vessel segmentation, outperforming traditional CNNs in many cases. For example, Swin Transformers and Multiple Instance Learning ViTs (MIL-ViTs) have been used to detect subtle retinal changes associated with systemic diseases like diabetes and hypertension [49].

In addition, integrating multimodal data, which combines imaging, text, and molecular data, or may of the same modalities, has opened new frontiers in oculomics. For instance, AI models can now analyse retinal images alongside EHRS and genomic data to predict disease progression and treatment outcomes. This multimodal approach has been particularly useful in studying complex conditions such as DR, and AMD, where genetic factors play a significant role in disease pathogenesis [50], [51].

The application of AI extends beyond imaging to the realm of genomics and gene editing. Advances in next-generation sequencing and single-cell RNA sequencing have generated vast amounts of genomic and transcriptomic data, which can be analysed using AI to identify disease-associated genes and pathways. For example, AI-driven genomic analysis has identified key genetic variants associated with AMD, DR and glaucoma [52]–[54]. These insights have paved the way for gene editing technologies such as CRISPR-Cas9, which hold promise for treating inherited retinal diseases. AI models are also used to optimise gene editing protocols, predict off-target effects, and design personalised therapeutic interventions for individual patients [55].

*7) **LLMS and Future AI in the OCULOMICS**:* The emergence of Large Language Models (LLMs) such as GPT-4 has further expanded the scope of AI in healthcare. LLMs can analyse vast amounts of textual data, including scientific literature, clinical notes, and patient records, to extract insights and generate hypotheses [56]. However, in the field of oculomics, LLM is in the early stages and requires improvement; some study results show [57], [58] that knowledge gained by LLM is usually taken by humans. Although LLMS represent a cutting-edge branch of AI with growing potential in oculomics, it is equally important to understand the broader trajectory of AI as it intersects with medical and retinal research. The evolution of AI, from early origins to present-day applications, forms the foundation for modern techniques that now reshape retinal imaging.

*8) **Overview on the Evolution of AI**:* In a nutshell, the emergence of AI has reshaped the dynamics of almost every field, specifically healthcare. The short description, limitations, evolution, and relevance to medicine are shown in Figure 3, and some related stuff is discussed here. In 1956, the emergence of AI took its main start from the Dartmouth College conference, which mainly consisted of symbolic AI, in other words, a rule-based system. However, due to the computational limit, the transition of the rule-based system into the classical ML occurred from 1966 to 1970. The wave of backpropagation was another milestone in 1980; despite the emergence of this technique, AI was not getting full attention due to the funding constraints, along with the expected results [59]. The era 1980-1990 is considered a winter era for AI, and again, the domain is shifted to statistical and classical ML. The Chronology of LENET Architecture, which spans from 1990 to 2012, laid the foundation for the emergence of the DL model and paved a new horizon for the future of AI [60], [61]. The DL model is a seismic change that is now non-stop in the current era, and day-to-day, new algorithms and models are emerging. The transition of AI from a theoretical to a practical tool has changed the dynamics of the research, academia and industrial world. The capabilities of AI now extend from the basic models to the complex, whether supervised or unsupervised.

III. Modern Techniques: The Rise of Oculomics

As mentioned earlier, the eye disease is retained in the retina. The same is also connected and affects the important parts of the body, such as the brain, heart, kidneys, etc. This type of disease is called systemic disease, a condition that affects the entire body or several organs, not just one part. The linking of the eyes with systemic diseases is named oculomics [1], [4]. The potential behind the oculomics expanded further by leveraging the existing retinal imaging research with the advancement of multiple data modalities. This can be gained by revealing the medical modalities. The modalities used so far in the field of ophthalmology are OCT, fluorescence angiography (FA), adaptive optics (AO), and FP for revealing the structural and functional changes in the ocular system [2], [3]. These modalities help provide enormous retinal imaging data and are widely used in the real world of medical vision. This imaging data emerged as the dataset used to mitigate the burden of eye diseases with respect to monitoring, therapeutic, prognostic and diagnosis, respectively [2]. The datasets are used in different case studies individually and combined for monitoring and identifying a variety of eye ailments like DR, GL, ME, and cataracts etc. The different retinal datasets are available publically to detect and classify eye diseases on time. These datasets have been very helpful so far and are used for different objectives of classical ocular diseases.

A. Retinal Imaging Techniques

OCT, FP, FA, and AO are the primary medical imaging modalities used to screen for visual disorders. OCT and FP, among the medical imaging modalities, play a pivotal role in screening visual disorders. Their non-invasive nature and detailed interpretation make them stand out. OCT, in particular, has become the gold standard for visualising retinal structures at micrometre resolution. The ability to provide cross-sectional images allows clinicians to analyze retinal layers for conditions such as macular edema, glaucoma, and AMD. The extended version of OCT, OCTA, captures the underlying mechanism of the blood flow of choroidal and retinal vasculature, providing valuable insights into retinal neovascularization and ischemic conditions [62].

For the past three decades of epidemiological studies in developed countries, fundus photography has been used as a standard for processing retinal imaging subjects to quantify

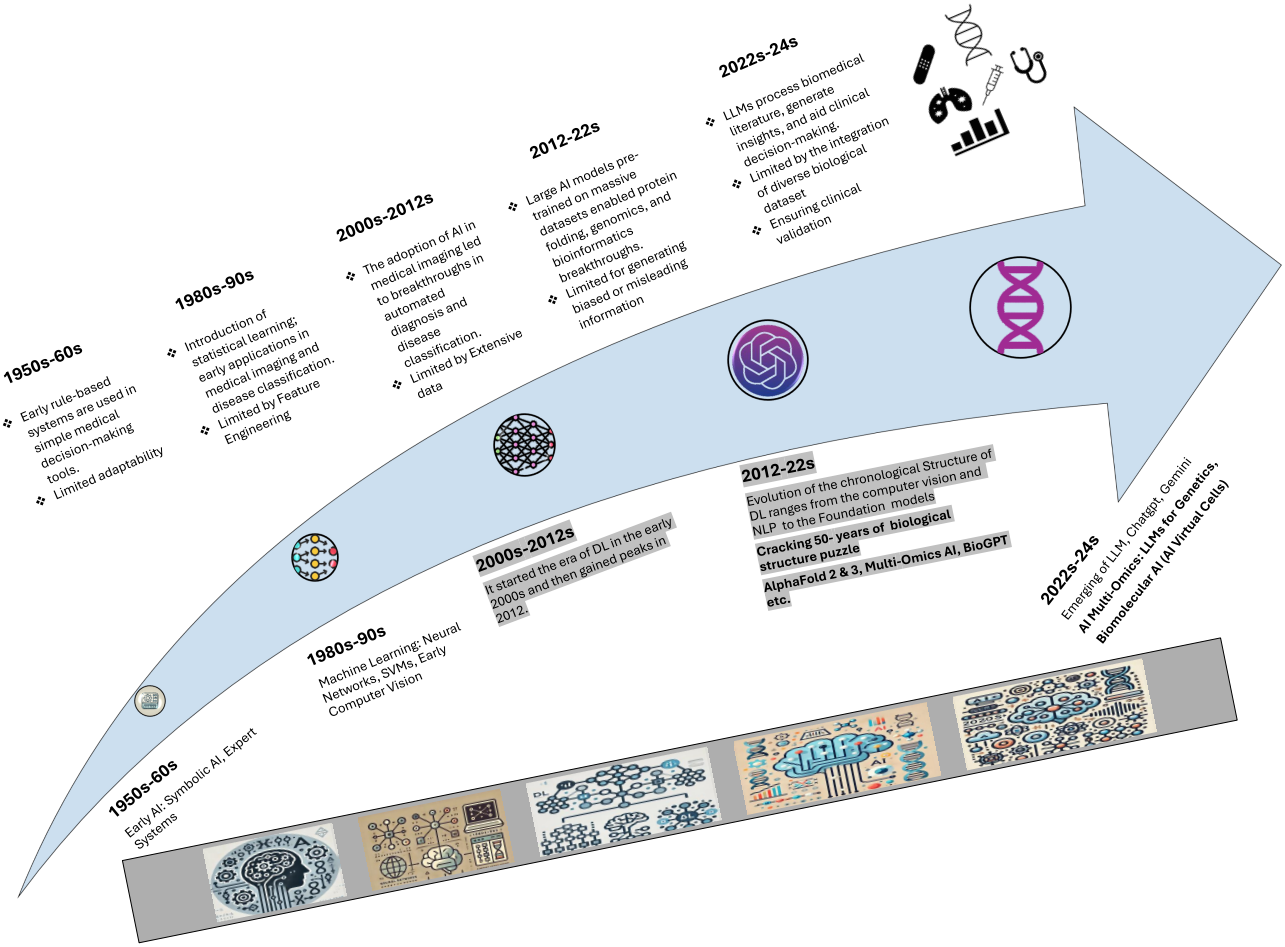

Fig. 3. illustrates a timeline that outlines the development of artificial intelligence, starting with symbolic rule-based systems in the 1950s and progressing to modern deep learning, foundation models, and large language models. This evolution emphasises important technological changes that have impacted the overall AI field, providing a basis for today's uses in healthcare and biomedical research.

the retinal vascular geometric parameters, including vessel tortuosity, fractal dimension (FD), width, diameter, and focal narrowing. The intuition behind the fundus is that the retina is the only part of the central nervous system (CNS) which can be seen through the ophthalmoscope. When the ophthalmologist looks through the ophthalmoscope into the eyeball, they are able to visualise the posterior part of the retina and the structure around it. This part of the retina, which is visible to the telescope, is called the ocular fundoscopy. FP remains one of the most widely used tools in retinal imaging. It captures detailed 2D retina images, including the optic disc, macula, and retinal vasculature. It is invaluable for screening conditions like DR, hypertensive retinopathy, and retinal vein occlusion. However, fundus photography's inability to provide depth information limits its application in detecting subtle changes in retinal layers. Similarly, Fluorescein angiography uses a fluorescent dye to highlight retinal and choroidal vasculature. It has been a critical tool for diagnosing retinal vein occlusion, AMD, and diabetic ME. Despite its diagnostic utility, the invasive nature of dye injection can pose risks to patients. Another non-invasive technique is AO. AO imaging corrects optical distortions to achieve cellular-level resolution. This technique allows for the visualisation of individual photoreceptors and capillary networks, providing insights into microvascular changes and cellular damage in diseases like hypertension and DR stages. Integrating any of the above approaches is also helpful in some cases [63] By combining imaging modalities like OCT, FP, and FA, we can comprehensively understand retinal structure and function. This multimodal imaging approach is increasingly being used in clinical practice, enhancing our ability to diagnose complex conditions with greater precision. Studies have shown that this technique significantly improves the efficiency of our diagnostic models compared to using a single imaging modality, providing reassurance about the progress we are making in the field [64].

B. *Publicly Available Retinal Datasets*

In the present day, the data is used as a tool for competing, from small tech companies to giants and from developing to developed countries. Data is valuable and works as a gold mine in the epoch of GEN-AI. In this context, the available data is getting more attention if found in large amounts, specifically in the field of the medical sciences. This data can emerge

as a dataset which can be used further in the real world of health research and drive innovations and discoveries [19]. Furthermore, gold-standard imaging techniques provide the opportunity for the creation of a dataset used as a benchmark for the validation and testing of real clinical trials in situ and in vivo. The advancement of retinal imaging techniques has created numerous publicly available datasets, which have become indispensable resources for researchers and physicians. These datasets are widely used for lesion detection, disease classification, and vessel segmentation [65]. For example, datasets such as **STARE** [66],**DRIVE** [67],**DIARETDB1** [68] ,**CHASE DB1**, [69] ,**HRF** [70], **E-ophtha** [71] , **MESSIDOR**, **MESSIDOR-2** [72] ,**KAGGLE-EyePACS** [73] ,**IDRiD** [74], **KAGGLE-APTOS** [75] , and **DDR** [76] have been instrumental in developing algorithms for detecting and classifying diabetic retinopathy, segmenting retinal vessels, and identifying other ocular pathologies.

Collectively, these publicly available datasets have established the foundation for advancements in image-based ophthalmic research, particularly in the automated detection and classification of retinal diseases. However, the diagnostic requirements and imaging targets vary significantly across different ocular conditions. To understand how these datasets contribute to disease-specific model development, it is important to contextualise their relevance across major retinal disorders.

In this survey, we therefore transition from the dataset overview into a focused discussion of key localized diseases—beginning with glaucoma, where structural deterioration of the optic nerve is a primary concern; followed by age-related macular degeneration, which involves degeneration of the macula; and finally diabetic retinopathy, where vascular abnormalities and lesion characteristics dominate. Each disease presents unique imaging biomarkers and machine learning challenges, necessitating tailored approaches in algorithm design and data representation.

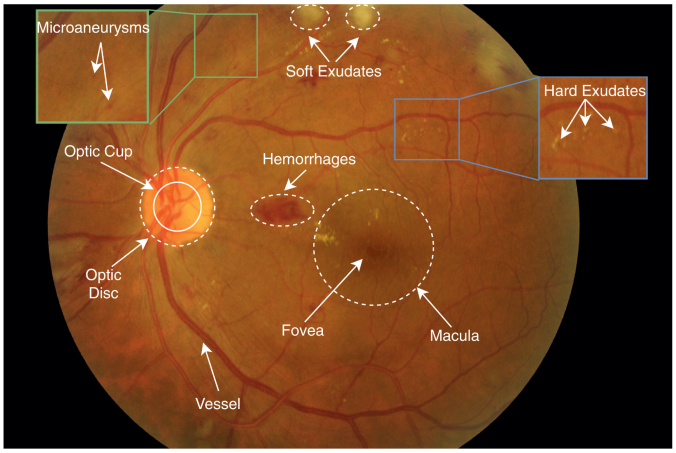

Fig. 4. An annotated fundus image reproduced from Li et al. [65], showing pathological markers including MAs, HMs, EXs, and anatomical regions like the fovea and optic disc.

Glaucoma: Glaucoma is a long-term and gradually worsening condition of the optic nerve that results in permanent loss of vision and stands as one of the primary causes of blindness worldwide. It affects an estimated 76 million people as of 2020 and is projected to impact over 111.8 million by 2040 [77]. Elevated intraocular pressure is often linked to the disease, but many patients also experience normal-tension glaucoma, illustrating the condition's complex origins. The disease affects both the structural and functional health of the eye, especially through the degeneration of retinal ganglion cells (GC) and harm to the optic nerve head. Clinically, a key biomarker for diagnosing glaucoma is the cup-to-disc ratio (CDR), which quantifies the size of the optic cup relative to the optic disc and reflects the cupping of the optic nerve [78], [79].

Two primary imaging modalities, FP and OCT, are widely used to detect and monitor glaucomatous changes. OCT provides high-resolution cross-sectional views of the retinal nerve fibre layer (RNFL) and GC complex, enabling early identification of nerve fibre loss. In contrast, FP offers a top-down view of the optic nerve head, allowing for disc cupping evaluation and broader topographic interpretation [80]. Mehta et al [81] demonstrated that combining OCT and FP could improve accuracy in detecting structural glaucomatous damage through CDR-based assessment.In the last decade, DL has significantly reshaped the landscape of glaucoma diagnostics. Early ML models often relied on handcrafted features like texture and colour histograms to classify glaucoma cases [82]. These models provided a baseline but lacked scalability and robustness in real-world scenarios.

With the rise of CNNS, researchers shifted to end-to-end learning pipelines capable of automatically extracting hierarchical visual features [10]. Li et al. [83] developed a CNN-based glaucoma detection model trained on FP images, reporting performance metrics on par with experienced ophthalmologists. Thakur et al. [84] developed a multimodal deep learning framework that combined OCT and visual field (VF) data, effectively capturing the disease's structural and functional aspects. Similarly, Asaoka et al. [85]built on this research by employing deep regression models to forecast future visual field deterioration using only baseline OCT scans, providing a useful clinical resource for long-term monitoring.

More recently, attention-based architectures, specifically ViTs, have shown promise in retinal image analysis. Unlike CNNS, which rely on localised filters, transformer models can capture long-range dependencies and global context, making them suitable for capturing subtle glaucomatous patterns across the optic disc and RNFL regions. Liu et al. [86] applied transformer models to fundus images and reported superior classification performance and generalizability across datasets compared to conventional CNN-based baselines.

Age-Related Macular Degeneration: Age-Related Macular Degeneration is a name that suggests that it can affect the center vision part of the eye, the macula. Eyesight declines with the passage of time and can impact daily routine activities. It is complicated in the early and later stages, as the early stage shows minimal symptoms and can cause vision loss in the former stage [87]. In the case of unattended patients, AMD cases will be projected to be 288 million patients by 2040 [88]. Due to this, it poses an important public health challenge. Different case studies have used an AI-driven retinal diagnostic model to address this ailment. Mark and Andres designed the

study [89], [90]to quantify and detect the abnormality of the macula in Fundus images using ML. This model helped to assess the risk of progression, along with the prediagnosis of AMD.

A comprehensive study [91] which leverages the ML algorithm, categorises the AMD stages along with the data-driven technique and develops a Computer-Aided Diagnosis framework. This model is classified into No, Intermediate, Dry, and Wet AMD, and the results are compared with those of the other studies. This model has a better result. Likewise, unlike typical ML, a deep learning algorithm is employed in different AMD patient case studies. Due to their hierarchical, deep structure, the DL model gets an improved result by interacting directly with the hidden parameters and acting as an autonomous model.

[92] presents a DL-AI-driven solution for automated AMD detection and differential diagnosis, leveraging vision transformers, data augmentation and Swin transformer through the fundus images to enhance accuracy, efficiency, and cost-effectiveness. Likewise, a DL model integrates with the local outlier Factor algorithm's goal to classify the AMD from the OCT images. The generalizations are tested on the unseen dataset, a Duke dataset, which performs very well in the early detection of AMD [93].

Diabetic Retinopathy: When insulin production is not enough in the human body, it can raise the glucose level in the blood and lead to diabetes. Type 1 and 2 both have a high socioeconomic effect. However, type 2 requires more attention as it leads to other chronic diseases associated with heart, kidney, nose, nerve and eye diseases [94].

DR is one of the complications directly related to the eye. The complication involves swelling of the vasculature of the retina, causing the leaking of blood and fluids, and, in the later stage, it leads to vision loss if unattended. The pathophysiology of the DR risk is distributed like this: the retinal vascular leakage causes fluid accumulation in the vitreous humour. Similarly, MAs and HMs are red lesions by the same soft and hard EX. A bright lesion disrupts normal vision, and the lesion advances in the shape of Neovascularization, leading to severe vision as portrayed in the Figure 4. The commonly occurring retinal lesions include MAs, intraretinal HMs, and venous beading (characterised by alternating areas of venous dilation and constriction). Additionally, intraretinal microvascular abnormalities, hard EX (lipid deposits), and retinal neovascularization are also recognised as common types of lesions. Since these DR risks are distributed into binary and multiple classes, in multiple classes, there are often five classes, which are No, mild, moderate, severe and PDR. In contrast, in the binary, these classes are non-proliferative DR (NPDR), further subdivided into the mild, moderate, and Severe DR. Subsequently, the remaining stages are considered as PDR [95]–[97].

Over the past two decades, much research has been conducted to prevent DR from the classical algorithms to the modern ones [98]. A tetragonal local octa pattern method is proposed by [99]to represent the features of Fundus images. Subsequently, authors in [100] used traditional ML algorithms such as SVM, decision tree and RF. likewise, the study conducted at [101]employed the approach of Gabor wavelet encased with the Adaboost classifier to classify the DR. For the binary classification of a DR, a range of studies [102]–[105] has been available using the CNN model, which has gained a significant result.

Furthermore, the binary and multi-classification of DR leveraging the DL model is evidenced in these studies. For instance, in [106], Rego employed InceptionV3 to detect DR using RGB and texture features. Pamadi et al. [107] developed binomial and multinomial classification models for fundus images using MobileNetV2, while Saranya et al. [108] utilised the DenseNet-121 model to identify DR from fundus images. Additionally, various architectures of EfficientNet were explored in [109]. Some studies proposed hybrid models that combined DL models for feature extraction with traditional ML models for classification. For example, Boral and Thorat [110]used InceptionV3 for representation learning in conjunction with an SVM for DR classification.

Ensemble models (EM) are widely recognised in medical imaging as an effective strategy to improve classification accuracy and model robustness by aggregating outputs from multiple base learners [111]. Jiang et al. [112]introduced an EM for DR detection, incorporating three CNN models. Furthermore, Adaboost was employed to efficiently integrate the outputs of these DL models through learned weights. The image preprocessing steps included resizing into 520x520x3, rotation, translation, mirroring, contrast adjustment, sharpness enhancement, and brightness modification.

Advancements in DL models have led to the incorporation of a self-attention mechanism, significantly enhancing both textual and visual applications and developing Vision Transformers. ViTs demonstrate superior capability in encoding spatial equivariance compared to the convolutional layers found in traditional CNNs and continue to perform exceptionally well [48], [113].

Kumar et al. [114] conducted a comparison of three DL architectures for DR detection: Transformer-based networks (specifically Swin-Transformer and Vision-Transformer), CNNs (including EfficientNet and ResNet), and a multi-layered perceptron (MLP Mixer). Their research revealed that transformer-based models outperformed the other architectures in terms of accuracy.

In another study, Yu et al., [49] introduced a Multiple Instances Learning Vision Transformer (MIL-ViT) DL model, which undergoes training in two phases: initially, it is pre-trained on a large fundus image dataset, followed by fine-tuning for the specific task of DR detection. Performance assessments utilising the [75] and RFMiD2020 [115] datasets indicated that MIL-ViT surpassed CNN models.

Adak et al. [116] developed an ensemble of transformer models that integrates four distinct models to evaluate the severity of DR. Furthermore, Gu et al. [117] proposed a DR grading model that combines a vision transformer with residual attention. This model features two primary components: (1) a feature extraction block based on the transformer, which emphasises retinal haemorrhage and exudate areas, and (2) a grading prediction block employing residual attention to capture different spatial regions corresponding to various

classes. For further insights into the application of transformers in medical imaging, readers are encouraged to explore recent studies [118], [119].

These diseases and their detection are pivotal and are used in the vivio and vito, and have established a foundation for the field of oculomics. However, diseases covered through the above data sets may not have the potential to get deep insight into the underlying mechanism of genotype-wide association. These are primarily focused on phenotypic analysis, which limits their utility for genotypic studies. To fully realise the prospective of oculomics, the acquisition of datasets needs to be extended to include cohort-based studies that integrate clinical patient records, high-throughput data, and structural and functional imaging data. Such comprehensive datasets would enable researchers to explore the genetic and molecular underpinnings of ocular and systemic diseases, paving the way for personalised medicine.

C. Automated Retinal Vascular Morphology: A Pathway to Oculomics

The circulatory system plays a critical role in systemic health, and the dysfunction often manifests in the retina's microvascular structures. Retinal circulation, characterised by the unique accessibility and transparency, provides an invaluable opportunity to study vascular health non-invasively. Blood viscosity, vessel length, and vessel diameter are critical determinants of vascular resistance and have been closely examined within the retinal vasculature to uncover systemic disease mechanisms [120]. In connection with these features and parameters, a vascular structure encased in the retinal circulation gained close attention to unveil the mechanism underlying these structures. In recent decades, interest has gone beyond the classical techniques of oculomics due to its relationship with systemic diseases like both types of diabetes, CVDs and dementia [121], [122].

Microvasculature features of the eye in the vivo assessment of FP allow the computerised approach to measuring the retinal vessel calibre of the arterioles, venules, and the ratio between these. These measurements are the gold standard for oculomics, which can link with systemic diseases [50]. Studies showed that hypertension and atherosclerosis are linked with the narrowing of the arteries [120], [123], and the DR is associated with the dilation of retinal veins [124]. In addition, increasing touristy of the retinal arteries is interlinked with hypercholesterolemia and hypertension [125], [126].

Initially, retinal calibres were measured manually, a tedious process requiring human computation and traditional formulas. However, manual vessel segmentation often produces suboptimal results, which can hinder model performance. Over the past few decades, extensive research has been conducted to automate this process and extract retinal vascular features. Significant advancements have been achieved through various approaches, including feature-based methods, unsupervised graph-based techniques, and supervised deep learning models [127]–[133]. These developments have led to the emergence of multiple software tools for clinical and research applications. However, most of these tools remain semi-automated, necessitating human intervention to correct vessel segmentation and identify features such as bifurcations, tortuosity, branching angles, artery/vein diameters, widths, and FD.

To address these limitations, *AutoMorph*, a fully automated software package, was developed by Yukun Zhou et al [1], leveraging DL models to autonomously measure retinal calibres without human intervention. The *AutoMorph* pipeline consists of four key components: preprocessing, image quality grading, anatomical segmentation, and morphological feature measurement. The anatomical segmentation and morphological feature extraction stages play a crucial role in advancing *oculomics*, an emerging field that explores the relationship between retinal and systemic diseases. The third stage of *AutoMorph* enables precise segmentation of the optic disc/cup, vessels, arteries, and veins. The final stage extracts key vascular morphology metrics, including tortuosity (via distance measurement, squared curvature, and density) for each artery and vein, and fractal dimension to quantify vessel complexity. Additionally, it measures retinal vascular calibres for central retinal arterioles equivalent (CRAE) and central retinal venular equivalent (CRVE), along with their arteriolar-to-venular ratio (AVR), and enables macular region-specific assessments.

With advancements in retinal imaging software, researchers can now efficiently quantify retinal vascular features, segment major arteries and veins, and capture the fine-grained structural details of smaller vessels with high precision. These developments have expanded the potential of retinal imaging beyond ophthalmic disease diagnosis, providing valuable insights into systemic health conditions. Increasing evidence suggests that retinal vascular morphology serves as a biomarker for various systemic diseases, including hypertension, diabetes, cardiovascular disease, and neurodegenerative disorders. By enabling automated, high-throughput retinal vascular analysis, *AutoMorph* and similar technologies contribute to a deeper understanding of the intricate connections between retinal changes and systemic pathophysiology, reinforcing the growing role of *oculomics* in predictive medicine and disease monitoring. page

D. Evolution of Oculomics: From Classical to Future Frameworks

The field of oculomics is transforming from traditional medical imaging to modern multi-modality and omics data integration. This shift is driven by three current paradigms: Automated AI software tools, big data, and high-resolution ophthalmic imaging.

Figure 5 represents the classical paradigm of eye research before oculomics emerged. In this era, diagnostic pipelines were built on conventional image preprocessing methods such as contrast enhancement, region-of-interest cropping, and manual noise reduction. Machine learning or early deep learning models were applied to handcrafted features, such as texture patterns, vessel widths, and colour intensity, extracted from fundus photography or optical coherence tomography. The outputs of these pipelines were typically limited to binary or multi-class classification (e.g., disease present or absent), with low interpretability, of localised optometry diseases, and minimal systemic relevance. This approach lacked scalability

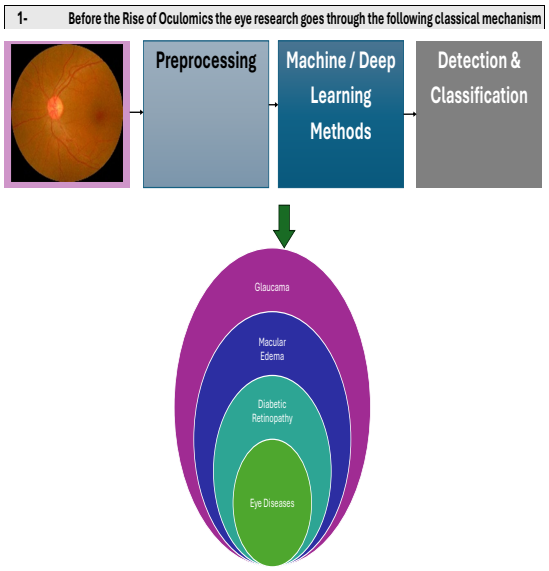

Fig. 5. Classical Techniques in Eye Research : Classical diagnostic workflow in early eye research, focusing on image preprocessing and handcrafted feature analysis. This figure establishes the foundation for how early computational methods approached retinal diagnostics before oculomics.

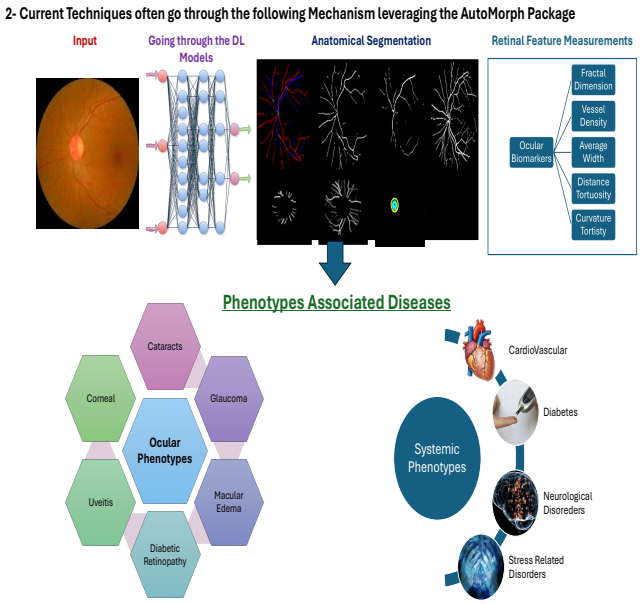

Fig. 6. Current Techniques Using AutoMorph: Contemporary oculomics framework leveraging AI-based vascular feature extraction tools like AutoMorph. It illustrates the shift toward automated and quantifiable retinal phenotyping to support both ocular and systemic disease research.

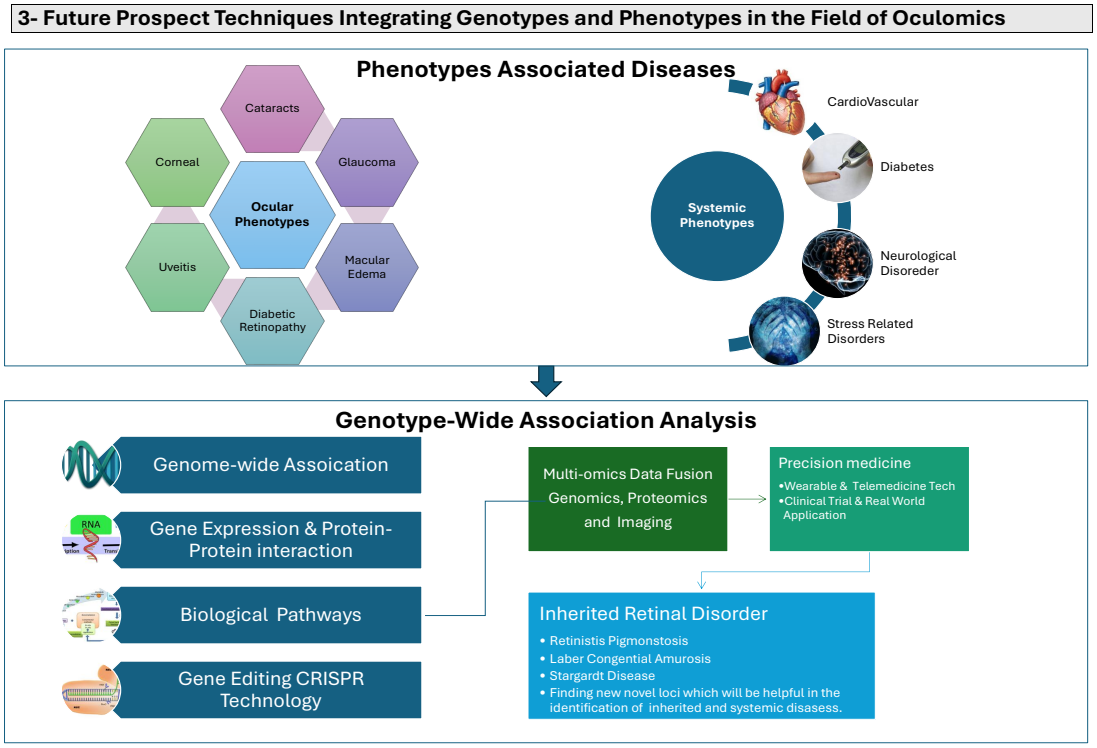

Fig. 7. Future Prospects in Oculomics: Future outlook for oculomics as a multi-modal healthcare platform integrating imaging, genomics, and computational biology. The figure outlines a vision for system-level precision diagnostics driven by AI and omics technologies.

and failed to capture the full complexity of vascular and neural changes in the retina that could indicate broader systemic health conditions.

Figure 6 demonstrates the current framework in oculomics, pitched by automated DL-based image segmentation tools such as AutoMorph. This phase is portrayed by automated vascular feature extraction from retinal images, allowing researchers to quantify high-resolution phenotypic traits. AutoMorph provides structured morphological outputs and objective measures such as CRAE, CRVE, AVR, tortuosity, and fractal dimension. These features not only support ocular disease classification, such as for glaucoma or diabetic retinopathy, but also serve as non-invasive alternatives for systemic conditions like hypertension, cardiovascular disease, and neurological degeneration. This middle phase in the oculomics evolution enables large-scale population analysis and deep phenotyping at scale.

Figure 7 envisions the future direction of oculomics, where phenotypic data from retinal imaging are integrated with molecular-level information to create a fully multimodal healthcare platform. This framework combines imaging biomarkers with genomic, transcriptomic, proteomic, and metabolomic data layers. Technologies such as genome-wide association studies, protein-protein interaction networks, CRISPR-based gene editing, and pathway enrichment models are embedded within this vision. This integrated pipeline aims to enable precise risk stratification, identify novel therapeutic targets, and personalise disease prediction and management.

This figure underscores the ambition of oculomics to evolve from a diagnostic subfield of ophthalmology into a central node in precision medicine. Figures 5 through 7 collectively offer a visual synthesis of this paper's thematic arc. They represent the chronological and conceptual development from basic retinal diagnostics, through current AI-driven phenotyping, and toward a highly integrative, multi-omics-enabled future.

This transition also aligns with the paper's overall structure: beginning with classical foundations, moving through tools like AutoMorph, and culminating in the future of AI-integrated oculomics. By placing these stages adjacent to each other, the infographics demonstrate the evolution of the field from organ-centric diagnostics to a comprehensive approach, where the eye serves as a window to understanding human health at both the cellular and molecular levels. Such a framework supports the central argument of this paper: oculomics is not merely a subfield of ophthalmology, but a rapidly evolving interdisciplinary platform for next-generation healthcare innovation. Building on the current state of AI-enabled retinal imaging, the subsequent section expands into the systemic implications, demonstrating how retinal biomarkers are increasingly used to infer cardiovascular, neurological, and metabolic diseases.

IV. Linking Eye and Systemic Diseases

A. The Eye as a Mirror of Systemic Health

The eyes are considered a window for the mirror of the soul of health. What does this mean to us? This means that looking at the eyes of the person can be interpreted, and the other person's concealed attitudes, thoughts, and emotions can be guessed [134]. The same is true; the eyes are the only organ in the human body that acts as a window to see the world, making them unique organs to care for. In connection with other non-communicable diseases like rheumatic, neurodegenerative, hypertensive and diabetic Mellitus, eyes will help us to detect them in a non-invasive manner and act as biomarkers for these fatal diseases.

The World Health Organisation estimated that 2.2 billion people in the world are suffering from eye diseases and are being prevented to the tune of one billion of them. Therefore, other than an ophthalmologist, researchers and scientists are keenly interested in unveiling the hidden patterns and mechanisms to analyse with the latest research, emulsified with the holistic approach to care for our eye health and save the whole body [135]. In addition, a recent study revealed that the eye also manifests a variety of stress diseases in which oxidative stress is crucial. This leads to the onset of different degenerative and chronic disorders such as cancer, atherosclerosis, coronary arteries, kidney, neurological, Respiratory, and Rheumatoid arthritis diseases [96]

The advancement in retinal imaging technology, like the FP, OA, OCT and OCTA, has not only enhanced the diagnostic structure related to sight-threatening retinal diseases but also opened the door to leveraging ocular markers to detect systemic disease. This can further anticipate the onset and act as a non-invasive surrogate biomarker for its grading and treatment response [4]. In a nutshell, the eye is a mirror and window for the soul of health, exhibiting numerous diseases. Here, we review some key diseases from recent articles, particularly focusing on chronic disorders with respect to ageing.

B. Systemic Diseases Linked to Retinal Changes

1) ***Cardiovascular Diseases:*** Blood vessels residing in the retinal image can be visualised noninvasively, as they are encased with the features of vessel calibre and offer insight into the systemic health of the cardiovascular system and future risk [6]. The stratifying of CV risk is the key challenge which exacerbates the cause of the mortality rate globally. The identification and management of CVDs risk is calculated by considering various variables such as age, smoking status, body mass index (BMI), cholesterol and glucose level, blood pressure, and gender, induced by the patient's history and blood samples, leveraging the Framingham score and pooled cohort equations [136]. To strengthen this mechanism further, phenotypic information can mitigate the burden of this disease. In addition, the mentioned features are combined in a manner that identifies the types of risk, which are calculated for 10 years.

The study carried out in the [137] shows that some of the unavailable parameters can exacerbate the function of stratifying the CVDs risk. This study shows that cholesterol values were missing in a 10-year risk score and less than 30% for patients; this lags as fasting blood drawn is needed to obtain these data. In contrast, in some studies, BMI is used as an alternative marker of lipids in the preliminary assessment of CVDs. Thus, retinal imaging may be another surrogate

marker to predict cardiovascular risk non-invasively and serve as a diagnostic tool for CVDs, offering insights into systemic vascular health [15].

The retinal vasculature is a microcosm of the body's circulatory system, and its structure and function changes can indicate underlying cardiovascular conditions. Microvasculature abnormalities like the widening and narrowing of venular and arteriolar are strongly connected with Coronary Artery Disease (CAD), hypertension and atherosclerosis [138]. These changes are frequently detected prior to clinical symptoms of CVDs, making the eye a valuable biomarker for early identification. Hypertensive retinopathy, which is characterised by vascular changes such as arteriolar narrowing, HMs, and EXs, is a direct consequence of systemic hypertension. Studies have shown that people with hypertensive retinopathy face an increased risk of stroke, heart attack, and heart failure [139]. Likewise, the other studies explain that [50] low retinal vascular FD and density are responsible for the high risk of mortality incidence, like renal failure, CVD, hypertension, etc.

Furthermore, a condition associated with hypertension and atherosclerosis called retinal vein occlusion has also been linked with CV events. Studies reveal that patients with retinal vein occlusion had a higher risk of developing CAD and a higher mortality rate compared to the general population [7], [140], [141].

2) ***Diabetes and Diabetic Retinopathy****:* Diabetes, or in other words, Diabetes Mellitus (DM), is one of the most pressing challenges in the socio-health scenario of the 21st century. It has experienced a dramatic rise in the incidence rate for the past three decades. The international diabetes Federation estimates that, to the tune of 536.5 million, the adult age group suffered from diabetes in the year 2021. This number could reach 738.2 million by 2045 [142].

This disease association is characterised by hypercalcemia, which further exacerbates other complications like CVDS, kidney failure, and vision loss and imposes substantial burdens on the economy and healthcare system [94]. Microvasculature complications damage the small blood vessels linked to the different organs and diseases like Diabetic Nephropathy, Neuropathy and Retinopathy [143]. Microvasculature plays an important role in maintaining tumorigenesis and organ health, and the human eye, i.e., the retinal fundus, serves as a window for in vivo assessment [50]. OCT and OCTA have facilitated the non-invasive assessment of retinal microvasculature [144].

Studies have shown that individuals with diabetes exhibit alterations in retinal vascular calibre, including wider venular diameters, which are associated with an increased risk of developing diabetes and its complications. A comprehensive analysis with 18,771 participants indicated that a larger retinal venular diameter is linked to a higher risk of developing Type-2 diabetes over a median follow-up duration of 10 years, even when controlling for possible confounding factors [145].

Moreover, retinal texture analysis has emerged as a potential tool for the early detection of diabetes-related retinal changes. A recent study utilising OCT-derived texture characteristics found that changes in retinal texture are concurrent with biological retinal changes, suggesting that texture analysis could serve as a biomarker for the early diagnosis of DR [142]. Circulating biomarkers have also been found, which also play a role in predicting diabetic complications. Higher levels of immunocomplexes and immunoglobulin M anti-cardiolipin antibodies have been observed in diabetes patients with vascular complications, suggesting their potential as biomarkers for DR [146].

Similarly, the progression of DR is closely linked to systemic metabolic control, evidenced by some recent studies, which underline the implication of advanced glycation end products (AGEs) and oxidative stress in the development of DR. The accumulation of AGEs in the retinal vasculature triggers the complication of inflammation and endothelial dysfunction; by the same oxidative stress, it worsens the cellular damage [96], [147]. These complications, on the one side, contribute to the progression of DR and, on the other side, reflect the systemic disease related to diabetes, like neuropathy and nephropathy. For example, the presence of DR has been associated with a higher risk of diabetic kidney disease, underscoring the interconnectedness of microvascular complications [148], [149].

3) ***Neurodegenerative Diseases****:* The retina, an extension of the CNS, bridges the functional and structural relationship with the brain and acts as a window to identify early neurodegenerative diseases (NDDs). This unique role of the eye is increasingly considered as a window into the brain, manifesting different NDDs like multiple sclerosis, Parkinson's, and Alzheimer's diseases (AD) [3].

Retinal imaging has revealed structural and functional alterations in patients with NDDs. For example, RNFL thinning and GC layer loss have been observed in individuals with AD. Retinal microvascular analysis provides valuable insights into AD. Studies have shown that individuals with a high genetic risk of AD exhibit reduced macular thickness even before symptoms appear [150], and patients with AD have significantly thinner central macula compared to healthy controls [151]. Additionally, retinal microvascular changes, such as narrower venules and increased vessel tortuosity, may reflect vascular abnormalities associated with AD-related brain pathology, suggesting that retinal imaging could serve as a robust and reliable biomarker for the early detection and monitoring of AD and dementia [152]–[154].

Similarly, in Parkinson's disease, retinal thinning and dopaminergic cell loss in the retina have been linked to disease severity and progression [155], [156]. Currently, OCT has been utilized to quantify these changes, reflecting the progression of neurodegenerative processes impacting the brain. In addition, it has shown notable progress in detecting early signs of multiple sclerosis, with thinning of RNFL linked to disease activity and disability [157] Using imaging techniques other than the retinal and OCT, such as hyperspectral imaging, has further improved the ability to detect subtle retinal changes associated with neurodegeneration. Hyperspectral imaging allows us to visualise the cellular and molecular changes that occur in the retina, unlocking insight into the intricate mechanisms of disease [158]. These recent and other upcoming advances can open the door to a deeper understanding of how these conditions develop and progress, sparking a sense of curiosity and participation among researchers and clinicians.

V. Future Directions in Oculomics

Despite advancements in the field of oculomics from the classic to the modern. The emergence of AI models and their multi-faceted functions opens a door for interdisciplinary programs to dive into and solve socioeconomic and socio-health problems. Many of the studies included in this review paper tackle the localised and associated diseases of the eyes. However, this field still needs more attention to tackle these problems in one go.

Here are future directions to heighten this field: design and develop a robust, monolithic, reliable and reproducible Automatic diagnosis system (ADS) to act as a life-saving tool for clinical and industrial research.

1) It is important to mention that the current retinal imaging datasets mainly focus on phenotypic characteristics, such as lesion segmentation, disease classification, and vascular analysis. However, they lack genetic and molecular data, limiting our understanding of ocular disease progression and systemic correlations. This gap is particularly evident in diseases such as DR, AMD, and glaucoma, where genotypic variations play a critical role in disease progression and treatment response. A major limitation of existing datasets is that they do not capture the progression of gene expression changes at different disease stages. For example, in DR, we currently lack information on:
   a) Gene expression variations associated with early, moderate, and proliferative DR stages.
   b) Patterns of arterial, venous, and capillary alterations and their correlation with gene activity.
   c) Molecular pathways linking DR to cardiovascular risks, including blood pressure, BMI, lipid levels, and systemic inflammation markers.

   This cannot be covered by the existing public dataset, such as those used in [66]–[76]. Expanding epidemiological studies, such as cohort and longitudinal approaches, are essential and will cover the genetic sequencing data from the same patients, allowing for cross-comparison of gene expression, imaging biomarkers, and clinical factors. Tracking the same patients over time will help us to understand the underlying mechanism and result in a reliable outcome.

   Likewise, this will create retinal imaging datasets that include multi-omics data, such as genomics, transcriptomics, proteomics, and metabolomics—which are crucial to uncovering disease mechanisms at a systems level. This approach will allow researchers to study the genetic inclination to retinal diseases, track disease progression through molecular signatures, and establish links between ocular and systemic health. This chain will be interlinked with fostering interdisciplinary collaboration in areas like ophthalmology, data science, computer science, bioinformatics, molecular biology, and life sciences, opening a door for the success of oculomics. Similarly, the easily accessible multi-dataset (open access) will be a gold mine for institutional and healthcare research. The policymakers engage to ensure its practical implementation regarding data privacy and security to innovate the advancement in oculomics.
2) Expanding the retinal imaging capabilities to work with a diverse range of imaging, like OCT, OCTA, OA, fundus and infrared imaging. The Automorph package still has the same limitation: they are only suitable for the fundus images and cannot be relied on if its modalities are other than this. A diverse range of images should be integrated, which will be suitable for all the modalities of retinal images. This improvement will help us with the subtle retinal changes in the cellular and vasculature network of the eyes and act as ADS for localised and systemic diseases like hypertension, diabetes and neurodegenerative conditions.
3) Foundation model and domain shifting are the future of medical image analysis; these two are scarce in oculomics. Domain shifting is hard to correlate with the FP as it is well suitable for the OCT, and this can be achieved by shifting histoimaging of different tissues into the domain of eye tissue. However, the question arises as to why this model cannot be applied to all the modalities of optic systems. However, there is promise in this methodology, and it could be a popular approach in the future. Subsequently, the foundation model is trained on the enormous, diverse dataset and, by the same fine-tuning through a large number of tasks, produces reliable models. This model is found rare in the study of the retina and can be quite helpful in promoting ophthalmology. For example, the retina is linked with different diseases, including CVD. Finding the biomarkers for CVD with respect to retinal imaging. Creating a different model outcome like the features of carotid arteries correlates with the retinal imaging, the same for the serum lipidomics, sleep monitoring and oral microbiome dataset. Exploring the dataset directly connected with CVD and is associated with retinal imaging through the statistical model. Once a linkage is found and at the end, we add these models via the foundation model. This mechanism will be another way of contributing to eye research. In addition, this will maximise the transition of the research setting to routine clinical usage and could be expandable to portable retinal imaging devices to work as an ADS tool, which will also be helpful for the easily accessible remote regions of third-world countries.
4) The black box experience is the Elephant in the room, which is still challenging; however, the explainable AI solves some parts of it and goes further. This field itself needs attention. However, they have solved real-life puzzles. In connection with this, Explainable AI can also heighten the medical vision domain and help us identify which morphological patterns are responsible for systemic diseases through the DL system.
5) LLM is another buzzword in today's era and is trained on almost the world's puzzle. However, there is still room for oculomics, and we should focus on applications like the NYUTron [159], which is trained on 750,000 patients for routine clinical notes. Expanding to eye research can mitigate the burden on health practitioners.

Likewise, the LLM medical specialist model Llava-Med [160] and PathChat [161] demonstrate promising biomedical and histopathology imaging capabilities. There is a dire need for oculomics research communities to design an application specific to retinal systems to uncover complex patterns in one go.

6) Finally, it pertains to mention that despite the inclination of AI in the medical domain and the advancement in AI-based medical and ocular applications, they are still in the translational stage, and their benefits in clinical practice remain challenging. To fully utilise the potential of AI in oculomics medical trials, these key challenges need to be addressed.
    a) The integration of multiple data modalities as discussed earlier
    b) The development of transparent and explainable AI models encased with the code of conduct for data sharing and model validation.
    c) The collaboration between the AI researcher, clinician and healthcare practitioner ensures the care of AI-based tools relevant to the needs of stakeholders of the public health sector.
    d) The oculomics domain expert should be familiar with the rapid advancement of AI technology and tools. This will enable him to navigate the world and solve real-time problems in a routine clinical environment.

VI. Conclusion

Our detailed survey presents a broad exploration of the evolution of retinal imaging, tracing its path from classical techniques such as fundus photography and early machine learning approaches to the emerging era of oculomics powered by artificial intelligence. The transition from traditional vision-based diagnostics to deep phenotyping frameworks demonstrates the expanding role of the retina as a non-invasive biomarker for systemic health. Critical gaps remain despite significant advancements, such as the development of automated tools, the rise of multimodal AI frameworks, and the emergence of vision transformers. The disparity of datasets, the integrational paradigm lack between clinical, genetic, and imaging data, and limited demographic diversity constrain real-world deployment. Additionally, AI systems' interpretability and adaptation to heterogeneous clinical environments remain open challenges. As oculomics advances, it offers a unique opportunity to unify molecular, phenotypic, and clinical insights. This field could further nurture early diagnosis, risk prediction, and personalised healthcare by enriching an inclusive, longitudinal, and ethically governed research infrastructure. Sooner or later, the eye may serve not only as a diagnostic tool but as a window into systemic health and human biology at large.

References

[1] Y. Zhou, S. K. Wagner, M. A. Chia, A. Zhao, M. Xu, R. Struyven, D. C. Alexander, P. A. Keane *et al.*, "Automorph: automated retinal vascular morphology quantification via a deep learning pipeline," *Translational vision science & technology*, vol. 11, no. 7, pp. 12–12, 2022.

[2] M. J. Ringel, E. M. Tang, and Y. K. Tao, "Advances in multimodal imaging in ophthalmology," *Therapeutic Advances in Ophthalmology*, vol. 13, p. 25158414211002400, 2021.

[3] S. G. Honavar, "Oculomics–the eyes talk a great deal," p. 713, 2022.

[4] S. K. Wagner, D. J. Fu, L. Faes, X. Liu, J. Huemer, H. Khalid, D. Ferraz, E. Korot, C. Kelly, K. Balaskas *et al.*, "Insights into systemic disease through retinal imaging-based oculomics," *Translational vision science & technology*, vol. 9, no. 2, pp. 6–6, 2020.

[5] Z. Zhu, Y. Wang, Z. Qi, W. Hu, X. Zhang, S. K. Wagner, Y. Wang, A. R. Ran, J. Ong, E. Waisberg *et al.*, "Oculomics: Current concepts and evidence," *Progress in Retinal and Eye Research*, p. 101350, 2025.

[6] H. Hanssen, L. Streese, and W. Vilser, "Retinal vessel diameters and function in cardiovascular risk and disease," *Progress in retinal and eye research*, vol. 91, p. 101095, 2022.

[7] L.-q. Lyu, H.-y. Cui, M.-y. Shao, Y. Fu, R.-x. Zhao, and Q.-p. Chen, "Computational medicine: past, present and future," *Chinese journal of integrative medicine*, pp. 1–10, 2021.

[8] H. Bansal, H. Luthra, and S. R. Raghuram, "A review on machine learning aided multi-omics data integration techniques for healthcare," *Data Analytics and Computational Intelligence: Novel Models, Algorithms and Applications*, pp. 211–239, 2023.

[9] D. S. Ting, C. Y. Cheung, Q. Nguyen, C. Sabanayagam, G. Lim, Z. W. Lim, G. S. Tan, Y. Q. Soh, L. Schmetterer, Y. X. Wang *et al.*, "Deep learning in estimating prevalence and systemic risk factors for diabetic retinopathy: a multi-ethnic study," *Npj Digital Medicine*, vol. 2, no. 1, p. 24, 2019.

[10] S. Hassan, S. B. Belhaouari, I. Amin *et al.*, "Deciphering the impact of diversity in cnn-based ensembles on overcoming data imbalance and scarcity in medical datasets: A case study on diabetic retinopathy," *Informatics in Medicine Unlocked*, vol. 49, p. 101557, 2024.

[11] U. Schmidt-Erfurth, A. Sadeghipour, B. S. Gerendas, S. M. Waldstein, and H. Bogunović, "Artificial intelligence in retina," *Progress in retinal and eye research*, vol. 67, pp. 1–29, 2018.

[12] E. E. Brown, A. A. Guy, N. A. Holroyd, P. W. Sweeney, L. Gourmet, H. Coleman, C. Walsh, A. E. Markaki, R. Shipley, R. Rajendram *et al.*, "Physics-informed deep generative learning for quantitative assessment of the retina," *Nature Communications*, vol. 15, no. 1, p. 6859, 2024.

[13] Y. Zhou, M. A. Chia, S. K. Wagner, M. S. Ayhan, D. J. Williamson, R. R. Struyven, T. Liu, M. Xu, M. G. Lozano, P. Woodward-Court *et al.*, "A foundation model for generalizable disease detection from retinal images," *Nature*, vol. 622, no. 7981, pp. 156–163, 2023.

[14] J. De Fauw, J. R. Ledsam, B. Romera-Paredes, S. Nikolov, N. Tomasev, S. Blackwell, H. Askham, X. Glorot, B. O'Donoghue, D. Visentin *et al.*, "Clinically applicable deep learning for diagnosis and referral in retinal disease," *Nature medicine*, vol. 24, no. 9, pp. 1342–1350, 2018.

[15] R. Poplin, A. V. Varadarajan, K. Blumer, Y. Liu, M. V. McConnell, G. S. Corrado, L. Peng, and D. R. Webster, "Prediction of cardiovascular risk factors from retinal fundus photographs via deep learning," *Nature biomedical engineering*, vol. 2, no. 3, pp. 158–164, 2018.

[16] J. De Fauw, P. Keane, N. Tomasev, D. Visentin, G. van den Driessche, M. Johnson, C. O. Hughes, C. Chu, J. Ledsam, T. Back *et al.*, "Automated analysis of retinal imaging using machine learning techniques for computer vision," *F1000Research*, vol. 5, p. 1573, 2017.

[17] R. Collins, "What makes uk biobank special?" *Lancet (London, England)*, vol. 379, no. 9822, pp. 1173–1174, 2012.

[18] S. Shilo, N. Bar, A. Keshet, Y. Talmor-Barkan, H. Rossman, A. Godneva, Y. Aviv, Y. Edlitz, L. Reicher, D. Kolobkov *et al.*, "10 k: a large-scale prospective longitudinal study in israel," *European journal of epidemiology*, vol. 36, no. 11, pp. 1187–1194, 2021.

[19] S. M. Khan, X. Liu, S. Nath, E. Korot, L. Faes, S. K. Wagner, P. A. Keane, N. J. Sebire, M. J. Burton, and A. K. Denniston, "A global review of publicly available datasets for ophthalmological imaging: barriers to access, usability, and generalisability," *The Lancet Digital Health*, vol. 3, no. 1, pp. e51–e66, 2021.

[20] N. Agarwal, Nupur, P. K. Paul, and S. K. Mishra, "Artificial intelligence and machine learning for analysis of multi-omics," in *Multi-Omics Analysis of the Human Microbiome: From Technology to Clinical Applications*. Springer, 2024, pp. 339–354.

[21] E. E. Pérez-Guerrero, M. R. Guillén-Medina, F. Márquez-Sandoval, J. M. Vera-Cruz, M. P. Gallegos-Arreola, M. A. Rico-Méndez, J. A. Aguilar-Velázquez, and I. A. Gutiérrez-Hurtado, "Methodological and statistical considerations for cross-sectional, case–control, and cohort studies," *Journal of Clinical Medicine*, vol. 13, no. 14, p. 4005, 2024.

[22] T. Vos, S. S. Lim, C. Abbafati, K. M. Abbas, M. Abbasi, M. Abbasifard, M. Abbasi-Kangevari, H. Abbastabar, F. Abd-Allah, A. Abdelalim *et al.*, "Global burden of 369 diseases and injuries in 204 countries and territories, 1990–2019: a systematic analysis for the global burden

of disease study 2019," *The lancet*, vol. 396, no. 10258, pp. 1204–1222, 2020.

[23] S. Wang, M. Liu, Y. Li, X. Zhang, M. Sun, Z. Wang, R. Li, Q. Li, Q. Li, Y. He *et al.*, "Recent advances in data-driven fusion of multi-modal imaging and genomics for precision medicine," *Information Fusion*, p. 102738, 2024.

[24] T. Pearson, Y. Chen, B. Dhillon, S. Chandran, J. van Hemert, and T. MacGillivray, "Multi-modal retinal scanning to measure retinal thickness and peripheral blood vessels in multiple sclerosis," *Scientific Reports*, vol. 12, no. 1, p. 20472, 2022.

[25] A. R. Ran, H. Y. Hui, C. Y. Cheung, and T. Y. Wong, "Artificial intelligence in ophthalmology iii: systemic disease prediction," in *Artificial Intelligence in Clinical Practice*. Elsevier, 2024, pp. 119–125.

[26] K. Jin and J. Ye, "Artificial intelligence and deep learning in ophthalmology: current status and future perspectives," *Advances in ophthalmology practice and research*, vol. 2, no. 3, p. 100078, 2022.

[27] M. H. Akpinar, A. Sengur, O. Faust, L. Tong, F. Molinari, and U. R. Acharya, "Artificial intelligence in retinal screening using oct images: A review of the last decade (2013–2023)," *Computer methods and programs in biomedicine*, vol. 254, p. 108253, 2024.

[28] S. J. V. Lee, Y. Q. Goh, W. Rojas-Carabali, C. Cifuentes-González, C. Y. Cheung, A. Arora, A. de-la Torre, V. Gupta, R. Agrawal *et al.*, "Association between retinal vessels caliber and systemic health: A comprehensive review," *Survey of Ophthalmology*, 2024.

[29] Z. Li, S. Yin, S. Wang, Y. Wang, W. Qiang, and J. Jiang, "Transformative applications of oculomics-based ai approaches in the management of systemic diseases: A systematic review," *Journal of Advanced Research*, 2024.

[30] K. Cholkar, S. R. Dasari, D. Pal, and A. K. Mitra, "Eye: Anatomy, physiology and barriers to drug delivery," in *Ocular transporters and receptors*. Elsevier, 2013, pp. 1–36.

[31] Q. Liang, X. Cheng, J. Wang, L. Owen, A. Shakoor, J. L. Lillvis, C. Zhang, M. Farkas, I. K. Kim, Y. Li *et al.*, "A multi-omics atlas of the human retina at single-cell resolution," *Cell genomics*, vol. 3, no. 6, 2023.

[32] M. D. Abràmoff, M. K. Garvin, and M. Sonka, "Retinal imaging and image analysis," *IEEE reviews in biomedical engineering*, vol. 3, pp. 169–208, 2010.

[33] C.-C. Chan, "Couching for cataract in china," *Survey of ophthalmology*, vol. 55, no. 4, pp. 393–398, 2010.

[34] N. Ghadiri, "The history of uveitis: from antiquity to the present day," *Eye*, pp. 1–4, 2024.

[35] C. Reeves and D. Taylor, "A history of the optic nerve and its diseases," *Eye*, vol. 18, no. 11, pp. 1096–1109, 2004.

[36] W. McMullen, "The evolution of the ophthalmoscope," *The British Journal of Ophthalmology*, vol. 1, no. 10, p. 593, 1917.

[37] G. Clare, J. H. Kempen, and C. Pavésio, "Infectious eye disease in the 21st century—an overview," *Eye*, pp. 1–14, 2024.

[38] S. J. Weiss and T. D. Papakostas, "Fluorescein angiography," in *Albert and Jakobiec's Principles and Practice of Ophthalmology*. Springer, 2022, pp. 2659–2682.

[39] T. Moutray, J. R. Evans, N. Lois, D. J. Armstrong, T. Peto, and A. Azuara-Blanco, "Different lasers and techniques for proliferative diabetic retinopathy," *Cochrane Database of Systematic Reviews*, no. 3, 2018.

[40] J. García-Feijoo, "Tonometry and intraocular pressure–where are we now?" *Journal-Tonometry and Intraocular Pressure–Where are we Now?*

[41] S. Aumann, S. Donner, J. Fischer, and F. Müller, "Optical coherence tomography (oct): principle and technical realization," *High resolution imaging in microscopy and ophthalmology: new frontiers in biomedical optics*, pp. 59–85, 2019.

[42] B. Remeseiro, V. Bolon-Canedo, D. Peteiro-Barral, A. Alonso-Betanzos, B. Guijarro-Berdiñas, A. Mosquera, M. G. Penedo, and N. Sánchez-Maroño, "A methodology for improving tear film lipid layer classification," *IEEE Journal of Biomedical and Health Informatics*, vol. 18, no. 4, pp. 1485–1493, 2014.

[43] Y.-Y. Liu, M. Chen, H. Ishikawa, G. Wollstein, J. S. Schuman, and J. M. Rehg, "Automated macular pathology diagnosis in retinal oct images using multi-scale spatial pyramid and local binary patterns in texture and shape encoding," *Medical image analysis*, vol. 15, no. 5, pp. 748–759, 2011.

[44] D. Veiga, N. Martins, M. Ferreira, and J. Monteiro, "Automatic microaneurysm detection using laws texture masks and support vector machines," *Computer Methods in Biomechanics and Biomedical Engineering: Imaging & Visualization*, vol. 6, no. 4, pp. 405–416, 2018.

[45] R. GeethaRamani and L. Balasubramanian, "Macula segmentation and fovea localization employing image processing and heuristic based clustering for automated retinal screening," *Computer methods and programs in biomedicine*, vol. 160, pp. 153–163, 2018.

[46] V. Gulshan, L. Peng, M. Coram, M. C. Stumpe, D. Wu, A. Narayanaswamy, S. Venugopalan, K. Widner, T. Madams, J. Cuadros *et al.*, "Development and validation of a deep learning algorithm for detection of diabetic retinopathy in retinal fundus photographs," *jama*, vol. 316, no. 22, pp. 2402–2410, 2016.

[47] D. S. W. Ting, C. Y.-L. Cheung, G. Lim, G. S. W. Tan, N. D. Quang, A. Gan, H. Hamzah, R. Garcia-Franco, I. Y. San Yeo, S. Y. Lee *et al.*, "Development and validation of a deep learning system for diabetic retinopathy and related eye diseases using retinal images from multiethnic populations with diabetes," *Jama*, vol. 318, no. 22, pp. 2211–2223, 2017.

[48] A. Dosovitskiy, L. Beyer, A. Kolesnikov, D. Weissenborn, X. Zhai, T. Unterthiner, M. Dehghani, M. Minderer, G. Heigold, S. Gelly, J. Uszkoreit, and N. Houlsby, "An image is worth 16x16 words: Transformers for image recognition at scale," 2021. [Online]. Available: https://arxiv.org/abs/2010.11929

[49] S. Yu, K. Ma, Q. Bi, C. Bian, M. Ning, N. He, Y. Li, H. Liu, and Y. Zheng, "Mil-vt: Multiple instance learning enhanced vision transformer for fundus image classification," in *Medical Image Computing and Computer Assisted Intervention–MICCAI 2021: 24th International Conference, Strasbourg, France, September 27–October 1, 2021, Proceedings, Part VIII 24*. Springer, 2021, pp. 45–54.

[50] S. M. Zekavat, V. K. Raghu, M. Trinder, Y. Ye, S. Koyama, M. C. Honigberg, Z. Yu, A. Pampana, S. Urbut, S. Haidermota *et al.*, "Deep learning of the retina enables phenome-and genome-wide analyses of the microvasculature," *Circulation*, vol. 145, no. 2, pp. 134–150, 2022.

[51] X. Li, X. Dong, W. Zhang, Z. Shi, Z. Liu, Y. Sa, L. Li, N. Ni, and Y. Mei, "Multi-omics in exploring the pathophysiology of diabetic retinopathy," *Frontiers in Cell and Developmental Biology*, vol. 12, p. 1500474, 2024.

[52] L. G. Fritsche, W. Igl, J. N. C. Bailey, F. Grassmann, S. Sengupta, J. L. Bragg-Gresham, K. P. Burdon, S. J. Hebbring, C. Wen, M. Gorski *et al.*, "A large genome-wide association study of age-related macular degeneration highlights contributions of rare and common variants," *Nature genetics*, vol. 48, no. 2, pp. 134–143, 2016.

[53] P. Gharahkhani, E. Jorgenson, P. Hysi, A. P. Khawaja, S. Pendergrass, X. Han, J. S. Ong, A. W. Hewitt, A. V. Segrè, J. M. Rouhana *et al.*, "Genome-wide meta-analysis identifies 127 open-angle glaucoma loci with consistent effect across ancestries," *Nature communications*, vol. 12, no. 1, p. 1258, 2021.

[54] K. Chen, Y. Wang, Y. Huang, X. Liu, X. Tian, Y. Yang, and A. Dong, "Cross-species scrna-seq reveals the cellular landscape of retina and early alterations in type 2 diabetes mice," *Genomics*, vol. 115, no. 4, p. 110644, 2023.

[55] E. H. Choi, S. Suh, A. E. Sears, R. Hołubowicz, S. R. Kedhar, A. W. Browne, and K. Palczewski, "Genome editing in the treatment of ocular diseases," *Experimental & molecular medicine*, vol. 55, no. 8, pp. 1678–1690, 2023.

[56] K. He, R. Mao, Q. Lin, Y. Ruan, X. Lan, M. Feng, and E. Cambria, "A survey of large language models for healthcare: from data, technology, and applications to accountability and ethics," *Information Fusion*, p. 102963, 2025.

[57] F. Antaki, S. Touma, D. Milad, J. El-Khoury, and R. Duval, "Evaluating the performance of chatgpt in ophthalmology: an analysis of its successes and shortcomings," *Ophthalmology science*, vol. 3, no. 4, p. 100324, 2023.

[58] B. K. Betzler, H. Chen, C.-Y. Cheng, C. S. Lee, G. Ning, S. J. Song, A. Y. Lee, R. Kawasaki, P. van Wijngaarden, A. Grzybowski *et al.*, "Large language models and their impact in ophthalmology," *The Lancet Digital Health*, vol. 5, no. 12, pp. e917–e924, 2023.

[59] R. Perez-Lopez, N. Ghaffari Laleh, F. Mahmood, and J. N. Kather, "A guide to artificial intelligence for cancer researchers," *Nature Reviews Cancer*, pp. 1–15, 2024.

[60] Y. LeCun, Y. Bengio, and G. Hinton, "Deep learning," *nature*, vol. 521, no. 7553, pp. 436–444, 2015.

[61] W. Rawat and Z. Wang, "Deep convolutional neural networks for image classification: A comprehensive review," *Neural computation*, vol. 29, no. 9, pp. 2352–2449, 2017.

[62] E. C. Greig, J. S. Duker, and N. K. Waheed, "A practical guide to optical coherence tomography angiography interpretation," *International journal of retina and vitreous*, vol. 6, pp. 1–17, 2020.

[63] W. Tan, X. Yao, T.-T. Le, B. Tan, L. Schmetterer, and J. Chua, "The new era of retinal imaging in hypertensive patients," *The Asia-Pacific Journal of Ophthalmology*, vol. 11, no. 2, pp. 149–159, 2022.

[64] E. Vaghefi, S. Hill, H. M. Kersten, and D. Squirrell, "Multimodal retinal image analysis via deep learning for the diagnosis of intermediate dry age-related macular degeneration: a feasibility study," *Journal of ophthalmology*, vol. 2020, no. 1, p. 7493419, 2020.

[65] T. Li, W. Bo, C. Hu, H. Kang, H. Liu, K. Wang, and H. Fu, "Applications of deep learning in fundus images: A review," *Medical Image Analysis*, vol. 69, p. 101971, 2021.

[66] A. Hoover, V. Kouznetsova, and M. Goldbaum, "Locating blood vessels in retinal images by piecewise threshold probing of a matched filter response," *IEEE Transactions on Medical imaging*, vol. 19, no. 3, pp. 203–210, 2000.

[67] J. Staal, M. D. Abràmoff, M. Niemeijer, M. A. Viergever, and B. Van Ginneken, "Ridge-based vessel segmentation in color images of the retina," *IEEE transactions on medical imaging*, vol. 23, no. 4, pp. 501–509, 2004.

[68] T. Kauppi, V. Kalesnykiene, J.-K. Kamarainen, L. Lensu, I. Sorri, A. Raninen, R. Voutilainen, H. Uusitalo, H. Kälviäinen, and J. Pietilä, "The diaretdb1 diabetic retinopathy database and evaluation protocol." in *BMVC*, vol. 1, no. 1. Citeseer, 2007, p. 10.

[69] C. G. Owen, A. R. Rudnicka, R. Mullen, S. A. Barman, D. Monekosso, P. H. Whincup, J. Ng, and C. Paterson, "Measuring retinal vessel tortuosity in 10-year-old children: validation of the computer-assisted image analysis of the retina (caiar) program," *Investigative ophthalmology & visual science*, vol. 50, no. 5, pp. 2004–2010, 2009.

[70] A. Budai, R. Bock, A. Maier, J. Hornegger, and G. Michelson, "Robust vessel segmentation in fundus images," *International journal of biomedical imaging*, vol. 2013, no. 1, p. 154860, 2013.

[71] E. Decenciere, G. Cazuguel, X. Zhang, G. Thibault, J.-C. Klein, F. Meyer, B. Marcotegui, G. Quellec, M. Lamard, R. Danno *et al.*, "Teleophta: Machine learning and image processing methods for teleophthalmology," *Irbm*, vol. 34, no. 2, pp. 196–203, 2013.

[72] E. Decencière, X. Zhang, G. Cazuguel, B. Lay, B. Cochener, C. Trone, P. Gain, J.-R. Ordóñez-Varela, P. Massin, A. Erginay *et al.*, "Feedback on a publicly distributed image database: the messidor database," *Image Analysis & Stereology*, pp. 231–234, 2014.

[73] E. Dugas, Jared, Jorge, and W. Cukierski, "Diabetic retinopathy detection," https://kaggle.com/competitions/diabetic-retinopathy-detection, 2015, kaggle.

[74] P. Porwal, S. Pachade, R. Kamble, M. Kokare, G. Deshmukh, V. Sahasrabuddhe, and F. Meriaudeau, "Indian diabetic retinopathy image dataset (idrid): a database for diabetic retinopathy screening research," *Data*, vol. 3, no. 3, p. 25, 2018.

[75] Karthik, Maggie, and S. Dane, "Aptos 2019 blindness detection," https://kaggle.com/competitions/aptos2019-blindness-detection, 2019, kaggle.

[76] T. Li, Y. Gao, K. Wang, S. Guo, H. Liu, and H. Kang, "Diagnostic assessment of deep learning algorithms for diabetic retinopathy screening," *Information Sciences*, vol. 501, pp. 511–522, 2019.

[77] Y.-C. Tham, X. Li, T. Y. Wong, H. A. Quigley, T. Aung, and C.-Y. Cheng, "Global prevalence of glaucoma and projections of glaucoma burden through 2040: a systematic review and meta-analysis," *Ophthalmology*, vol. 121, no. 11, pp. 2081–2090, 2014.

[78] I. V. Wagner, M. W. Stewart, and S. K. Dorairaj, "Updates on the diagnosis and management of glaucoma," *Mayo Clinic Proceedings: Innovations, Quality & Outcomes*, vol. 6, no. 6, pp. 618–635, 2022.

[79] M. K. Sahu, "A review on glaucoma: causes, symptoms, pathogenesis & treatment," *Journal of Clinical Research and Ophthalmology*, vol. 11, no. 1, pp. 001–004, 2024.

[80] L. J. Coan, B. M. Williams, V. K. Adithya, S. Upadhyaya, A. Alkafri, S. Czanner, R. Venkatesh, C. E. Willoughby, S. Kavitha, and G. Czanner, "Automatic detection of glaucoma via fundus imaging and artificial intelligence: A review," *Survey of ophthalmology*, vol. 68, no. 1, pp. 17–41, 2023.

[81] P. Mehta, C. A. Petersen, J. C. Wen, M. R. Banitt, P. P. Chen, K. D. Bojikian, C. Egan, S.-I. Lee, M. Balazinska, A. Y. Lee *et al.*, "Automated detection of glaucoma with interpretable machine learning using clinical data and multimodal retinal images," *American Journal of Ophthalmology*, vol. 231, pp. 154–169, 2021.

[82] R. Bock, J. Meier, L. G. Nyúl, J. Hornegger, and G. Michelson, "Glaucoma risk index: automated glaucoma detection from color fundus images," *Medical image analysis*, vol. 14, no. 3, pp. 471–481, 2010.

[83] Z. Li, Y. He, S. Keel, W. Meng, R. T. Chang, and M. He, "Efficacy of a deep learning system for detecting glaucomatous optic neuropathy based on color fundus photographs," *Ophthalmology*, vol. 125, no. 8, pp. 1199–1206, 2018.

[84] Y. Kihara, G. Montesano, A. Chen, N. Amerasinghe, C. Dimitriou, A. Jacob, A. Chabi, D. P. Crabb, and A. Y. Lee, "Policy-driven, multimodal deep learning for predicting visual fields from the optic disc and oct imaging," *Ophthalmology*, vol. 129, no. 7, pp. 781–791, 2022.

[85] L. Xu, R. Asaoka, H. Murata, T. Kiwaki, Y. Zheng, M. Matsuura, Y. Fujino, M. Tanito, K. Mori, Y. Ikeda *et al.*, "Improving visual field trend analysis with oct and deeply regularized latent-space linear regression," *Ophthalmology Glaucoma*, vol. 4, no. 1, pp. 78–88, 2021.

[86] C. Playout, R. Duval, M. C. Boucher, and F. Cheriet, "Focused attention in transformers for interpretable classification of retinal images," *Medical Image Analysis*, vol. 82, p. 102608, 2022.

[87] Y. Gao, F. Xiong, J. Xiong, Z. Chen, Y. Lin, X. Xia, Y. Yang, G. Li, and Y. Hu, "Recent advances in the application of artificial intelligence in age-related macular degeneration," *BMJ Open Ophthalmology*, vol. 9, no. 1, 2024.

[88] W. L. Wong, X. Su, X. Li, C. M. G. Cheung, R. Klein, C.-Y. Cheng, and T. Y. Wong, "Global prevalence of age-related macular degeneration and disease burden projection for 2020 and 2040: a systematic review and meta-analysis," *The Lancet Global Health*, vol. 2, no. 2, pp. e106–e116, 2014.

[89] M. J. van Grinsven, Y. T. Lechanteur, J. P. van de Ven, B. van Ginneken, C. B. Hoyng, T. Theelen, and C. I. Sánchez, "Automatic drusen quantification and risk assessment of age-related macular degeneration on color fundus images," *Investigative ophthalmology & visual science*, vol. 54, no. 4, pp. 3019–3027, 2013.

[90] A. García-Floriano, Á. Ferreira-Santiago, O. Camacho-Nieto, and C. Yáñez-Márquez, "A machine learning approach to medical image classification: Detecting age-related macular degeneration in fundus images," *Computers & Electrical Engineering*, vol. 75, pp. 218–229, 2019.

[91] A. A. Abd El-Khalek, H. M. Balaha, N. S. Alghamdi, M. Ghazal, A. T. Khalil, M. E. A. Abo-Elsoud, and A. El-Baz, "A concentrated machine learning-based classification system for age-related macular degeneration (amd) diagnosis using fundus images," *Scientific Reports*, vol. 14, no. 1, p. 2434, 2024.

[92] K. Xu, S. Huang, Z. Yang, Y. Zhang, Y. Fang, G. Zheng, B. Lin, M. Zhou, and J. Sun, "Automatic detection and differential diagnosis of age-related macular degeneration from color fundus photographs using deep learning with hierarchical vision transformer," *Computers in Biology and Medicine*, vol. 167, p. 107616, 2023.

[93] T. He, Q. Zhou, and Y. Zou, "Automatic detection of age-related macular degeneration based on deep learning and local outlier factor algorithm," *Diagnostics*, vol. 12, no. 2, p. 532, 2022.

[94] S. Azeem, U. Khan, and A. Liaquat, "The increasing rate of diabetes in pakistan: A silent killer," *Annals of medicine and surgery*, vol. 79, 2022.

[95] R. Sarki, K. Ahmed, H. Wang, and Y. Zhang, "Automatic detection of diabetic eye disease through deep learning using fundus images: a survey," *IEEE access*, vol. 8, pp. 151 133–151 149, 2020.

[96] L. Wei, X. Sun, C. Fan, R. Li, S. Zhou, and H. Yu, "The pathophysiological mechanisms underlying diabetic retinopathy," *Frontiers in Cell and Developmental Biology*, vol. 10, p. 963615, 2022.

[97] Z. Khan, F. G. Khan, A. Khan, Z. U. Rehman, S. Shah, S. Qummar, F. Ali, and S. Pack, "Diabetic retinopathy detection using vgg-nin a deep learning architecture," *IEEE Access*, vol. 9, pp. 61 408–61 416, 2021.

[98] Z. Yang, T.-E. Tan, Y. Shao, T. Y. Wong, and X. Li, "Classification of diabetic retinopathy: Past, present and future," *Frontiers in Endocrinology*, vol. 13, p. 1079217, 2022.

[99] T. Nazir, A. Irtaza, Z. Shabbir, A. Javed, U. Akram, and M. T. Mahmood, "Diabetic retinopathy detection through novel tetragonal local octa patterns and extreme learning machines," *Artificial intelligence in medicine*, vol. 99, p. 101695, 2019.

[100] S. Gayathri, V. P. Gopi, and P. Palanisamy, "Diabetic retinopathy classification based on multipath cnn and machine learning classifiers," *Physical and engineering sciences in medicine*, vol. 44, no. 3, pp. 639–653, 2021.

[101] P. S. Washburn *et al.*, "Investigation of severity level of diabetic retinopathy using adaboost classifier algorithm," *Materials Today: Proceedings*, vol. 33, pp. 3037–3042, 2020.

[102] K. Xu, D. Feng, and H. Mi, "Deep convolutional neural network-based early automated detection of diabetic retinopathy using fundus image," *Molecules*, vol. 22, no. 12, p. 2054, 2017.

[103] M. T. Esfahani, M. Ghaderi, and R. Kafiyeh, "Classification of diabetic and normal fundus images using new deep learning method," *Leonardo Electron. J. Pract. Technol*, vol. 17, no. 32, pp. 233–248, 2018.

[104] G. T. Zago, R. V. Andreão, B. Dorizzi, and E. O. T. Salles, "Diabetic retinopathy detection using red lesion localization and convolutional neural networks," *Computers in biology and medicine*, vol. 116, p. 103537, 2020.

[105] S. Suriyal, C. Druzgalski, and K. Gautam, "Mobile assisted diabetic retinopathy detection using deep neural network," in *2018 Global medical engineering physics exchanges/pan American Health Care Exchanges (GMEPE/PAHCE)*. IEEE, 2018, pp. 1–4.

[106] S. Rêgo, M. Dutra-Medeiros, F. Soares, and M. Monteiro-Soares, "Screening for diabetic retinopathy using an automated diagnostic system based on deep learning: diagnostic accuracy assessment," *Ophthalmologica*, vol. 244, no. 3, pp. 250–257, 2021.

[107] A. M. Pamadi, A. Ravishankar, P. A. Nithya, G. Jahnavi, and S. Kathavate, "Diabetic retinopathy detection using mobilenetv2 architecture," in *2022 International Conference on Smart Technologies and Systems for Next Generation Computing (ICSTSN)*. IEEE, 2022, pp. 1–5.

[108] P. Saranya, S. K. Devi, and B. Bharanidharan, "Detection of diabetic retinopathy in retinal fundus images using densenet based deep learning model," in *2022 international mobile and embedded technology conference (MECON)*. IEEE, 2022, pp. 268–272.

[109] W. Mudaser, P. Padungweang, P. Mongkolnam, and P. Lavangnananda, "Diabetic retinopathy classification with pre-trained image enhancement model," in *2021 IEEE 12th Annual Ubiquitous Computing, Electronics & Mobile Communication Conference (UEMCON)*. IEEE, 2021, pp. 0629–0632.

[110] Y. S. Boral and S. S. Thorat, "Classification of diabetic retinopathy based on hybrid neural network," in *2021 5th International Conference on Computing Methodologies and Communication (ICCMC)*. IEEE, 2021, pp. 1354–1358.

[111] Inamullah, S. Hassan, N. A. Alrajeh, E. A. Mohammed, and S. Khan, "Data diversity in convolutional neural network based ensemble model for diabetic retinopathy," *Biomimetics*, vol. 8, no. 2, p. 187, 2023.

[112] H. Jiang, K. Yang, M. Gao, D. Zhang, H. Ma, and W. Qian, "An interpretable ensemble deep learning model for diabetic retinopathy disease classification," in *2019 41st annual international conference of the IEEE engineering in medicine and biology society (EMBC)*. IEEE, 2019, pp. 2045–2048.

[113] I. Amin, S. Shi, H. AlMarzouqi, Z. Aung, W. Ahmed, and P. Liatsis, "Kolmogorov-arnold vision transformer for image reconstruction in lung electrical impedance tomography," *IEEE Open Journal of the Computer Society*, 2025.

[114] N. S. Kumar and B. R. Karthikeyan, "Diabetic retinopathy detection using cnn, transformer and mlp based architectures," in *2021 International Symposium on Intelligent Signal Processing and Communication Systems (ISPACS)*. IEEE, 2021, pp. 1–2.

[115] S. Pachade, P. Porwal, D. Thulkar, M. Kokare, G. Deshmukh, V. Sahasrabuddhe, L. Giancardo, G. Quellec, and F. Mériaudeau, "Retinal fundus multi-disease image dataset (rfmid)," 2020. [Online]. Available: https://dx.doi.org/10.21227/s3g7-st65

[116] C. Adak, T. Karkera, S. Chattopadhyay, and M. Saqib, "Detecting severity of diabetic retinopathy from fundus images using ensembled transformers," *arXiv preprint arXiv:2301.00973*, 2023.

[117] Z. Gu, Y. Li, Z. Wang, J. Kan, J. Shu, and Q. Wang, "Classification of diabetic retinopathy severity in fundus images using the vision transformer and residual attention," *Computational Intelligence and Neuroscience*, vol. 2023, no. 1, p. 1305583, 2023.

[118] A. Parvaiz, M. A. Khalid, R. Zafar, H. Ameer, M. Ali, and M. M. Fraz, "Vision transformers in medical computer vision—a contemplative retrospection," *Engineering Applications of Artificial Intelligence*, vol. 122, p. 106126, 2023.

[119] E. Z. Ye, J. Ye, and E. H. Ye, "Applications of vision transformers in retinal imaging: A systematic review," *Authorea Preprints*, 2023.

[120] T. T. Nguyen and T. Y. Wong, "Retinal vascular manifestations of metabolic disorders," *Trends in endocrinology & metabolism*, vol. 17, no. 7, pp. 262–268, 2006.

[121] Y. Ebuchi, T. Nagaoka, D. Fukamachi, K. Kojima, N. Akutsu, N. Murata, Y. Saito, D. Kitano, H. Yokota, S. Yamagami *et al.*, "Comprehensive assessment of systemic arteriosclerosis in relation to the ocular resistive index in acute coronary syndrome patients," *Scientific Reports*, vol. 12, no. 1, p. 2321, 2022.

[122] L. Brazionis, N. Quinn, S. Dabbah, C. D. Ryan, D. M. Møller, H. Richardson, A. C. Keech, A. S. Januszewski, J. Grauslund, M. L. Rasmussen *et al.*, "Review and comparison of retinal vessel calibre and geometry software and their application to diabetes, cardiovascular disease, and dementia," *Graefe's Archive for Clinical and Experimental Ophthalmology*, vol. 261, no. 8, pp. 2117–2133, 2023.

[123] N. Cheung, D. A. Bluemke, R. Klein, A. R. Sharrett, F. A. Islam, M. F. Cotch, B. E. Klein, M. H. Criqui, and T. Y. Wong, "Retinal arteriolar narrowing and left ventricular remodeling: the multi-ethnic study of atherosclerosis," *Journal of the American College of Cardiology*, vol. 50, no. 1, pp. 48–55, 2007.

[124] T. Y. Wong, "Retinal vessel diameter as a clinical predictor of diabetic retinopathy progression: time to take out the measuring tape," *Archives of ophthalmology*, vol. 129, no. 1, pp. 95–96, 2011.

[125] C. Y.-l. Cheung, Y. Zheng, W. Hsu, M. L. Lee, Q. P. Lau, P. Mitchell, J. J. Wang, R. Klein, and T. Y. Wong, "Retinal vascular tortuosity, blood pressure, and cardiovascular risk factors," *Ophthalmology*, vol. 118, no. 5, pp. 812–818, 2011.

[126] C. G. Owen, A. R. Rudnicka, C. M. Nightingale, R. Mullen, S. A. Barman, N. Sattar, D. G. Cook, and P. H. Whincup, "Retinal arteriolar tortuosity and cardiovascular risk factors in a multi-ethnic population study of 10-year-old children; the child heart and health study in england (chase)," *Arteriosclerosis, thrombosis, and vascular biology*, vol. 31, no. 8, pp. 1933–1938, 2011.

[127] Q. Mirsharif, F. Tajeripour, and H. Pourreza, "Automated characterization of blood vessels as arteries and veins in retinal images," *Computerized Medical Imaging and Graphics*, vol. 37, no. 7-8, pp. 607–617, 2013.

[128] B. Dashtbozorg, A. M. Mendonça, and A. Campilho, "An automatic graph-based approach for artery/vein classification in retinal images," *IEEE Transactions on Image Processing*, vol. 23, no. 3, pp. 1073–1083, 2013.

[129] R. Estrada, M. J. Allingham, P. S. Mettu, S. W. Cousins, C. Tomasi, and S. Farsiu, "Retinal artery-vein classification via topology estimation," *IEEE transactions on medical imaging*, vol. 34, no. 12, pp. 2518–2534, 2015.

[130] O. Ronneberger, P. Fischer, and T. Brox, "U-net: Convolutional networks for biomedical image segmentation," in *Medical image computing and computer-assisted intervention–MICCAI 2015: 18th international conference, Munich, Germany, October 5-9, 2015, proceedings, part III 18*. Springer, 2015, pp. 234–241.

[131] F. Huang, B. Dashtbozorg, and B. M. t. H. Romeny, "Artery/vein classification using reflection features in retina fundus images," *Machine Vision and Applications*, vol. 29, no. 1, pp. 23–34, 2018.

[132] C. L. Srinidhi, P. Aparna, and J. Rajan, "Automated method for retinal artery/vein separation via graph search metaheuristic approach," *IEEE Transactions on Image Processing*, vol. 28, no. 6, pp. 2705–2718, 2019.

[133] A. Hatamizadeh, H. Hosseini, N. Patel, J. Choi, C. C. Pole, C. M. Hoeferlin, S. D. Schwartz, and D. Terzopoulos, "Ravir: A dataset and methodology for the semantic segmentation and quantitative analysis of retinal arteries and veins in infrared reflectance imaging," *IEEE Journal of Biomedical and Health Informatics*, vol. 26, no. 7, pp. 3272–3283, 2022.

[134] D. A. S. Ph.D, "The eyes are the windows to the soul," https://www.mentalhealth.com/library/the-eyes-are-the-windows-to-the-soul, 2024, accessed: 27 April 2025.

[135] XLab Health, "The soul and eyes: An influential psychiatrist analyses whether the eyes are the window to the soul and why it is important to take care of eye health," https://xlab.health/the-soul-and-eyes-an-influential-psychiatrist-analyses-whether-the-eyes-are-the-wind 2024, accessed: 27 April 2025.

[136] D. C. Goff Jr, D. M. Lloyd-Jones, G. Bennett, S. Coady, R. B. D'agostino, R. Gibbons, P. Greenland, D. T. Lackland, D. Levy, C. J. O'donnell *et al.*, "2013 acc/aha guideline on the assessment of cardiovascular risk: a report of the american college of cardiology/american heart association task force on practice guidelines," *Circulation*, vol. 129, no. 25_suppl_2, pp. S49–S73, 2014.

[137] R. S. Hira, K. Kennedy, V. Nambi, H. Jneid, M. Alam, S. S. Basra, P. M. Ho, A. Deswal, C. M. Ballantyne, L. A. Petersen *et al.*, "Frequency and practice-level variation in inappropriate aspirin use for the primary prevention of cardiovascular disease: insights from the national cardiovascular disease registry's practice innovation and clinical excellence registry," *Journal of the American College of Cardiology*, vol. 65, no. 2, pp. 111–121, 2015.

[138] C. Y.-l. Cheung, M. K. Ikram, C. Sabanayagam, and T. Y. Wong, "Retinal microvasculature as a model to study the manifestations of hypertension," *Hypertension*, vol. 60, no. 5, pp. 1094–1103, 2012.

[139] Z. Wang, L. Feng, M. Wu, F. Ding, C. Liu, G. Xie, and B. Ma, "Hypertensive retinopathy can predict stroke: A systematic review and meta-analysis based on observational studies: Running title: Htr

and stroke: Meta-analysis," *Journal of Stroke and Cerebrovascular Diseases*, p. 107953, 2024.

[140] M. L. Morellón, Y. L. Loureiro, and S. R. Bilbao, "Retinal venous occlusion and its association with atherosclerotic vascular disease," *Medicina Clínica (English Edition)*, 2024.

[141] A. Voigt, H. Elbaz, E. Böhm, P. Wild, K. Lackner, M. Beutel, I. Schmidtmann, O. Tu, J. Schattenberg, S. Konstantinides *et al.*, "Incidence of retinal vein occlusion and its association with mortality-results from the gutenberg health study," *Ophthalmology*, 2025.

[142] H. Sun, P. Saeedi, S. Karuranga, M. Pinkepank, K. Ogurtsova, B. B. Duncan, C. Stein, A. Basit, J. C. Chan, J. C. Mbanya *et al.*, "Idf diabetes atlas: Global, regional and country-level diabetes prevalence estimates for 2021 and projections for 2045," *Diabetes research and clinical practice*, vol. 183, p. 109119, 2022.

[143] G. Bereda, "Complication of diabetes mellitus: Microvascular and macrovascular complications," *Int. J. Diabetes*, vol. 3, pp. 123–128, 2022.

[144] S. Oliveira, P. Guimarães, E. J. Campos, R. Fernandes, J. Martins, M. Castelo-Branco, P. Serranho, P. Matafome, R. Bernardes, and A. F. Ambrósio, "Retinal oct-derived texture features as potential biomarkers for early diagnosis and progression of diabetic retinopathy," *Investigative Ophthalmology & Visual Science*, vol. 66, no. 1, pp. 7–7, 2025.

[145] C. Sabanayagam, W. K. Lye, R. Klein, B. E. Klein, M. F. Cotch, J. J. Wang, P. Mitchell, J. E. Shaw, E. Selvin, A. R. Sharrett *et al.*, "Retinal microvascular calibre and risk of diabetes mellitus: a systematic review and participant-level meta-analysis," *Diabetologia*, vol. 58, pp. 2476–2485, 2015.

[146] O. Simó-Servat, R. Simó, and C. Hernández, "Circulating biomarkers of diabetic retinopathy: an overview based on physiopathology," *Journal of Diabetes Research*, vol. 2016, no. 1, p. 5263798, 2016.

[147] L. Zhan, "Frontiers in understanding the pathological mechanism of diabetic retinopathy," *Medical Science Monitor: International Medical Journal of Experimental and Clinical Research*, vol. 29, pp. e939 658–1, 2023.

[148] M. Yamanouchi, M. Mori, J. Hoshino, K. Kinowaki, T. Fujii, K. Ohashi, K. Furuichi, T. Wada, and Y. Ubara, "Retinopathy progression and the risk of end-stage kidney disease: results from a longitudinal japanese cohort of 232 patients with type 2 diabetes and biopsy-proven diabetic kidney disease," *BMJ open diabetes research & care*, vol. 7, no. 1, 2019.

[149] J. Fang, C. Luo, D. Zhang, Q. He, and L. Liu, "Correlation between diabetic retinopathy and diabetic nephropathy: a two-sample mendelian randomization study," *Frontiers in Endocrinology*, vol. 14, p. 1265711, 2023.

[150] I. López-Cuenca, R. de Hoz, E. Salobrar-García, L. Elvira-Hurtado, P. Rojas, J. A. Fernández-Albarral, A. Barabash, J. J. Salazar, A. I. Ramírez, and J. M. Ramírez, "Macular thickness decrease in asymptomatic subjects at high genetic risk of developing alzheimer's disease: an oct study," *Journal of Clinical Medicine*, vol. 9, no. 6, p. 1728, 2020.

[151] Z. Farzinvash, M. Abutorabi-Zarchi, M. Manaviat, and H. Z. Mehrjerdi, "Retinal ganglion cell complex in alzheimer disease: comparing ganglion cell complex and central macular thickness in alzheimer disease and healthy subjects using spectral domain-optical coherence tomography," *Basic and clinical neuroscience*, vol. 13, no. 5, p. 675, 2022.

[152] Y.-T. Ong, S. Hilal, C. Y.-l. Cheung, X. Xu, C. Chen, N. Venketasubramanian, T. Y. Wong, and M. K. Ikram, "Retinal vascular fractals and cognitive impairment," *Dementia and geriatric cognitive disorders extra*, vol. 4, no. 2, pp. 305–313, 2014.

[153] C. Y.-l. Cheung, Y. T. Ong, M. K. Ikram, S. Y. Ong, X. Li, S. Hilal, J.-A. S. Catindig, N. Venketasubramanian, P. Yap, D. Seow *et al.*, "Microvascular network alterations in the retina of patients with alzheimer's disease," *Alzheimer's & Dementia*, vol. 10, no. 2, pp. 135–142, 2014.

[154] C. Czakó, T. Kovács, Z. Ungvari, A. Csiszar, A. Yabluchanskiy, S. Conley, T. Csipo, A. Lipecz, H. Horváth, G. L. Sándor *et al.*, "Retinal biomarkers for alzheimer's disease and vascular cognitive impairment and dementia (vcid): implication for early diagnosis and prognosis," *Geroscience*, vol. 42, pp. 1499–1525, 2020.

[155] M. Satue, M. Seral, S. Otin, R. Alarcia, R. Herrero, M. Bambo, M. Fuertes, L. Pablo, and E. Garcia-Martin, "Retinal thinning and correlation with functional disability in patients with parkinson's disease," *British Journal of Ophthalmology*, vol. 98, no. 3, pp. 350–355, 2014.

[156] R. Elanwar, H. Al Masry, A. Ibrahim, M. Hussein, S. Ibrahim, and M. M. Masoud, "Retinal functional and structural changes in patients with parkinson's disease," *BMC neurology*, vol. 23, no. 1, p. 330, 2023.

[157] G. Bsteh, H. Hegen, N. Krajnc, F. Föttinger, P. Altmann, M. Auer, K. Berek, B. Kornek, F. Leutmezer, S. Macher *et al.*, "Retinal layer thinning for monitoring disease-modifying treatment in relapsing multiple sclerosis—evidence for applying a rebaselining concept," *Multiple Sclerosis Journal*, vol. 30, no. 9, pp. 1128–1138, 2024.

[158] J. Yoon, "Hyperspectral imaging for clinical applications," *BioChip Journal*, vol. 16, no. 1, pp. 1–12, 2022.

[159] L. Y. Jiang, X. C. Liu, N. P. Nejatian, M. Nasir-Moin, D. Wang, A. Abidin, K. Eaton, H. A. Riina, I. Laufer, P. Punjabi *et al.*, "Health system-scale language models are all-purpose prediction engines," *Nature*, vol. 619, no. 7969, pp. 357–362, 2023.

[160] C. Li, C. Wong, S. Zhang, N. Usuyama, H. Liu, J. Yang, T. Naumann, H. Poon, and J. Gao, "Llava-med: Training a large language-and-vision assistant for biomedicine in one day," *Advances in Neural Information Processing Systems*, vol. 36, 2024.

[161] M. Y. Lu, B. Chen, D. F. Williamson, R. J. Chen, K. Ikamura, G. Gerber, I. Liang, L. P. Le, T. Ding, A. V. Parwani *et al.*, "A foundational multimodal vision language ai assistant for human pathology," *arXiv preprint arXiv:2312.07814*, 2023.