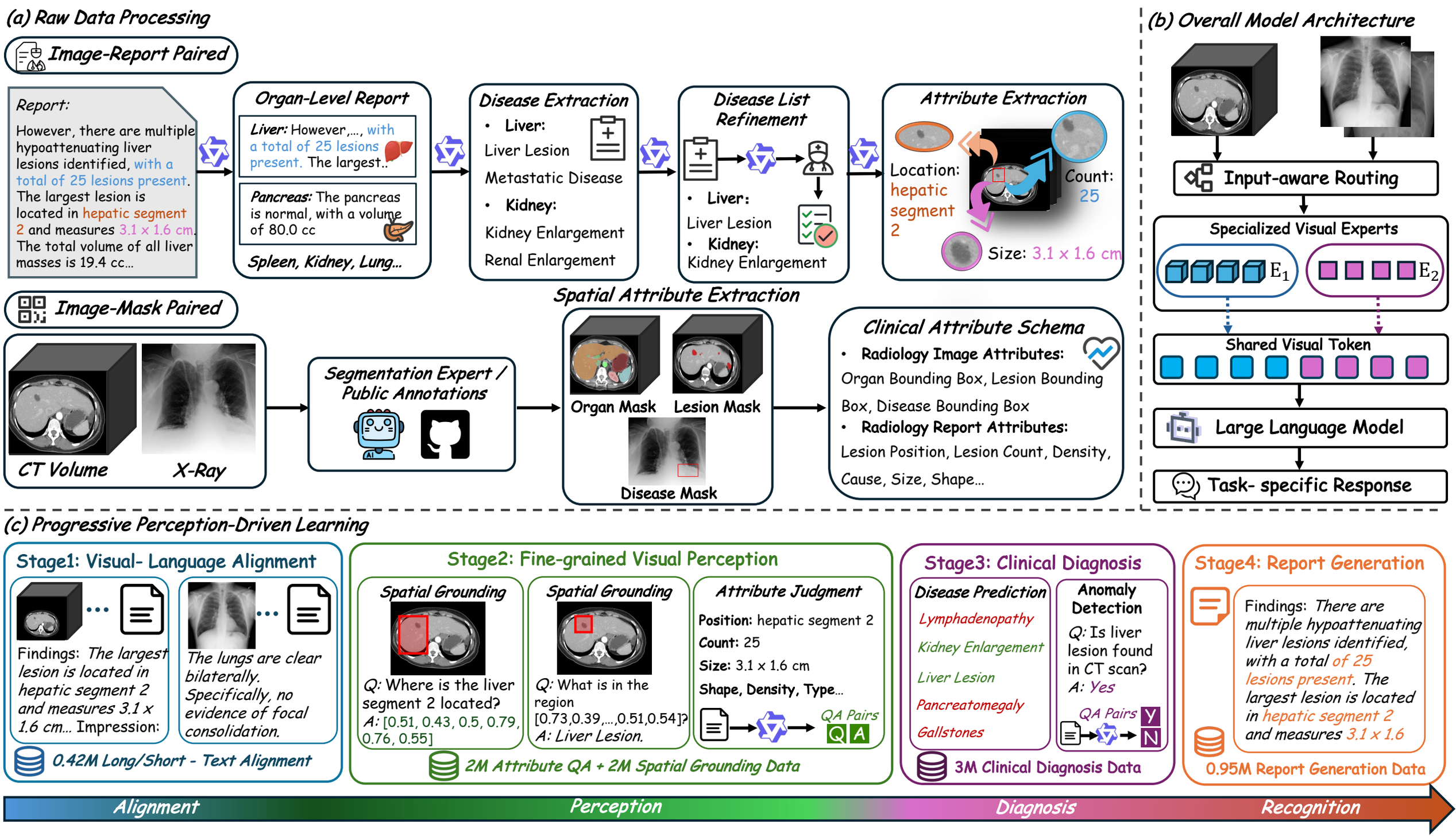
(a) Raw Data Processing
Image-Report Paired
Report:
However, there are multiple hypoattenuating liver lesions identified, with a total of 25 lesions present. The largest lesion is located in hepatic segment 2 and measures 3.1 x 1.6 cm. The total volume of all liver masses is 19.4 cc...
Organ-Level Report
Liver: However,..., with a total of 25 lesions present. The largest..
Pancreas: The pancreas is normal, with a volume of 80.0 cc
Spleen, Kidney, Lung...
Disease Extraction
Liver:
Liver Lesion
Metastatic Disease
Kidney:
Kidney Enlargement
Renal Enlargement
Disease List Refinement
Liver:
Liver Lesion
Kidney:
Kidney Enlargement
Attribute Extraction
Location: hepatic segment 2
Count: 25
Size: 3.1 x 1.6 cm
Image-Mask Paired
CT Volume
X-Ray
Segmentation Expert / Public Annotations
Spatial Attribute Extraction
Organ Mask
Lesion Mask
Disease Mask
Clinical Attribute Schema
Radiology Image Attributes:
Organ Bounding Box, Lesion Bounding Box, Disease Bounding Box
Radiology Report Attributes:
Lesion Position, Lesion Count, Density, Cause, Size, Shape...
(b) Overall Model Architecture
Input-aware Routing
Specialized Visual Experts
E1
E2
Shared Visual Token
Large Language Model
Task- specific Response
(c) Progressive Perception-Driven Learning
Stage1: Visual- Language Alignment
Findings: The largest lesion is located in hepatic segment 2 and measures 3.1 x 1.6 cm... Impression:
The lungs are clear bilaterally. Specifically, no evidence of focal consolidation.
0.42M Long/Short - Text Alignment
Stage2: Fine-grained Visual Perception
Spatial Grounding
Q: Where is the liver segment 2 located?
A: [0.51, 0.43, 0.5, 0.79, 0.76, 0.55]
Spatial Grounding
Q: What is in the region [0.73,0.39,...,0.51,0.54]?
A: Liver Lesion.
Attribute Judgment
Position: hepatic segment 2
Count: 25
Size: 3.1 x 1.6 cm
Shape, Density, Type...
QA Pairs
Q A
2M Attribute QA + 2M Spatial Grounding Data
Stage3: Clinical Diagnosis
Disease Prediction
Lymphadenopathy
Kidney Enlargement
Liver Lesion
Pancreatomegaly
Gallstones
Anomaly Detection
Q: Is liver lesion found in CT scan?
A: Yes
QA Pairs
Y
N
3M Clinical Diagnosis Data
Stage4: Report Generation
Findings: There are multiple hypoattenuating liver lesions identified, with a total of 25 lesions present. The largest lesion is located in hepatic segment 2 and measures 3.1 x 1.6
0.95M Report Generation Data
Alignment
Perception
Diagnosis
Recognition