Perception-Bench

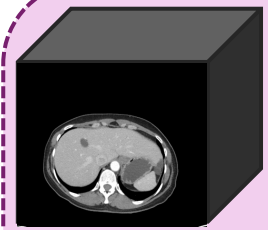

Q1: Is Liver Lesion found in this CT scan? Answer yes or no.

Answer: yes. $\xrightarrow{AUC}$ { Yes logit: 17.375, no logit: 16.25 }

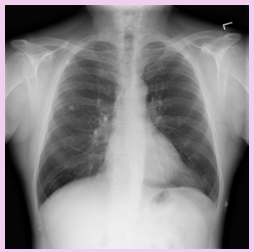

Q2: Is Lung Lesion found in this chest X-ray? Answer yes or no.

Answer: no. $\xrightarrow{AUC}$ { Yes logit: 16.25, no logit: 16.875 }

Anomaly Detection

Q2: which abnormality is most likely present? Choose the best answer. A. Pancreatomegaly B. Kidney EnlargementC. Splenomegaly D. Liver Lesion

Answer: A, D

Disease Prediction

Clinical Diagnosis

Q1: Please generate a medical report based on this image.

Answer: As compared to the previous radiograph, there is no relevant change. The monitoring and support devices are constant. No evidence of pneumothorax. No other acute interval changes.

Report Generation

Diagnostic Interpretation

RadSight

Fine-Grained Perception

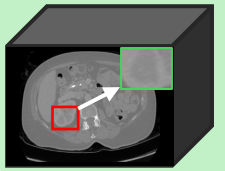

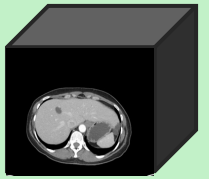

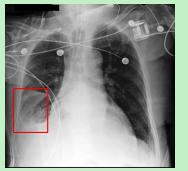

Q1: What is the size of the largest liver lesion?

Answer: 41x36 mm (largest)

Q2: Where is the largest lung nodule located?

Answer: upper lobe of the left lung

Attribute Judgement

Q3: Where is the Pneumonia located in this chest X-ray?

Answer: [0.67, 0.67, 0.91, 0.82]

Q4: Where is the heart located in this CT scan?

Answer: [0.38, 0.36, 0.88, 0.71, 0.71, 0.99]

Spatial Grounding

Q5: What abnormality is present in the region [0.05, 0.86, 0.14, 0.94] of this chest X-ray?

Answer: Pleural effusion

Q6: What is in the region [0.2, 0.28, 0.5, 0.28, 0.38, 0.55] of this CT scan?

Answer: Kidney Lesion

Spatial Understanding