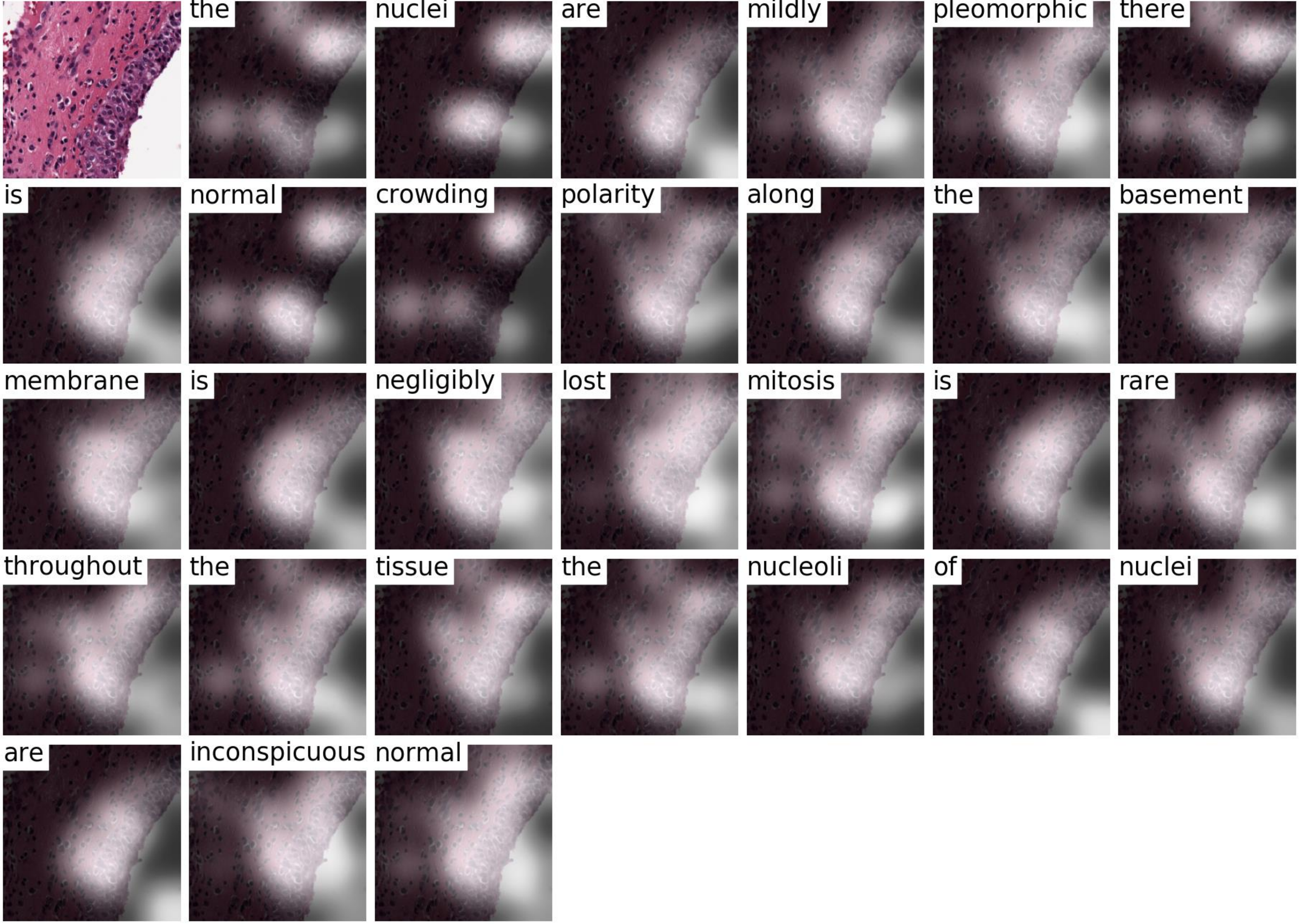
the
nuclei
are
mildly
pleomorphic
there
is
normal
crowding
polarity
along
the
basement
membrane
is
negligibly
lost
mitosis
is
rare
throughout
the
tissue
the
nucleoli
of
nuclei
are
inconspicuous
normal